



Reno-Hepatic Degeneration Caused by Extracts of *Calotropis Gigantea* Linn. in Albino Rats

Mahesh Mishra^{1*}, R. K Gautam², R. Mathur³

¹Vijay Raje Institute of Science and Management, Gwalior. Madhya Pradesh, India

²School of Life sciences, Khandari Campus, Agra University, Agra, Uttar Pradesh. India

³School of Studies in Zoology, Jiwaji University, Gwalior, Madhya Pradesh, India

ABSTRACT

The present study has been undertaken to evaluate renal and hepatic toxicity of the extracts of *Calotropis gigantea* Linn. Animals were divided into various control and experimental groups. Crude and ethanolic extracts were prepared and 150 and 300 mg/kg body weight doses were selected. At lower dose of 150 mg/kg body weight the toxicity was not so much pronounced whereas at 300 mg/kg body weight both extracts were found to be highly toxic. They produced hypertrophy of liver cells together with their nuclear degeneration and hyperchromasis. These changes can be due to improper carbohydrate metabolism. Kupffer cell population increased considerably. There was disruption of tunica intima of central vein. Tubular necrosis, loss of epithelium and shrinkage of glomeruli are common degenerative changes in the kidney at 300 mg/kg body weight dose.

KEY WORDS: Hyperchromasis, necrosis, kupffer cells, tunica intima.

INTRODUCTION

Since long the traditional medicinal systems of India, China and other countries of the world are using wealth of nature. The plants as a crude preparation or as extracts are used by folk doctors to treat a variety of ailments very effectively. Traditional medicines are very often believed to be nontoxic by rural and urban peoples. Plant (*Calotropis gigantea*) extracts and their flowers are used in treatment of ulcers, poisoning, leprosy, disorders of spleen and digestive system (improper motility), itching and piles. The white flowers are aphrodisiacs, light appetizers and anorexic. They are used to treat piles and breathing disorders and to increase salivation whereas red flowers have analgesic⁹, wormicidal and homeostatic properties. They are used to treat inflammation¹, cough, digestive disorders² and cancer⁷. The white latex is a good medicine to be used as purgative. Root bark is used in wound healing⁴. Root bark soaked in its own milk is used to treat cough¹⁰. Various active principles of *Calotropis* bark and sap are: Madar alban, Madar fluavil, Black acid resin, Caoutchouc (free), Yellow bitter resin (Active principle), Akundarin, Oxiopregnane - oligoglycosides now named as calotropin A and B, Calotropin D₁ and D₂. Cytotoxic principles of 'Akond mul' (root of *Calotropis gigantea*) include cardinoloids glycosides, calotropin frugosides and 4-O-β-D glucopyranosyl frugoside⁷. It's milky latex rich in lupeol, calotropin, calotoxin and uscharchin. Administration of chloroform extracts of *Calotropis gigantea* leaf and flower to streptozotocin-induced diabetes rats at a dose of 10, 20 and 50 mg/kg orally for 27 d lead to a significant decrease in lipid peroxidation, serum glutamic pyruvic transaminase, serum glutamic oxaloacetic

transaminase, alkaline phosphatase, cholesterol and triglyceride levels. Consequently, superoxide dismutase and catalase levels were significantly increased¹¹.

MATERIALS AND METHODS:

PLANT MATERIAL:

Roots of *Calotropis gigantea* obtained from the field were sliced and dried in shade and then powdered which acted as crude extract. The powder was also used to prepare 50% ethanolic extract by cold method. Standard doses of 150 and 300 mg/kg body weight were prepared for both extracts.

ANIMAL:

Albino rats of Sprague Dawley strain were selected from animal colony. They were housed under adequate conditions of temperature (25±1°C), relative humidity (65±10%), light and dark cycle (14:10H) and fed with standard pellets diet (Amrut Lab. Animal food diet, India) and water *ad libitum*. The doses were administered by intragastric catheter once a day at 10 AM for 14/21 days durations. Animals were divided into 10 groups, each group comprising of 6 animals.

1. Groups 1 and 2 were taken as control (vehicle) receiving 1% 1ml gum acacia for 14 and 21 days respectively.

2. Group 3 and 4 were administered crude extract for 14 days at doses 150 mg/kg body weight and 300 mg/kg body weight respectively while group 5 and 6 received the doses crude extract for 21 days at doses 150 and 300 mg/kg of weight respectively.

3. Group 7 and 8 were administered with ethanolic extract for 14 days at doses 150 mg/kg body weight and 300 mg/kg body weight respectively while group 8 and 9 received the ethanolic extract for 21 days at doses 150 and 300 mg/kg of weight respectively.

All the animals were sacrificed after 24 hours of the last treatment by using diethyl ether. Liver and kidney were taken out. Paraffin blocks were prepared using benzene methyl benzoate and 6 μ thick sections were obtained on rotary microtome and stained with eosin and haematoxylin and eosin. The change in cellular organization of tissues was studied under research microscope

RESULTS:

LIVER:

At 150 mg/kg body weight dose of crude extract the laminae showed large sinus among them. A number of hepatocytes showed hyperchromatic nuclei. The hepatocytes showed a variety of alterations in their structure. Some were completely deformed while others had degenerated nuclei and their cytoplasm was highly vacuolated. Between the laminae there was accumulation of fluid with debris [Figure L₃]. With ethanol extract the laminae were found to be better arranged, however, at some places hepatocytes were disorganized. Hyperchromasia of nuclei was less than that in crude extract treated animals. Some sinusoids had debris in them. Kupffer cell population seems to be increased [Figure L₂]. The hepatocytes showed hypertrophy in some regions where the nuclei were absent. Number of hyperchromatic nuclei was moderate. Some nuclei showed hyperchromasia of nuclear membrane only. Most of the large sinuses had debris. In some regions the hepatocytes had lost their characteristic feature and had various forms of deformation.

At 300 mg/kg body weight dose of crude extract the tunica intima of the large central vein was disrupted and the lumen had debris. Hyperchromatic nuclei had increased considerably. There was some hypertrophy of hepatocytes in some regions resulting in obliteration of the sinusoids [Figure L₃]. With ethanol extract the hepatocytes showed hyperchromasia of nuclear membrane. Most of the hepatocytes were deformed and in some of them nuclei were degenerated.

KIDNEYS:

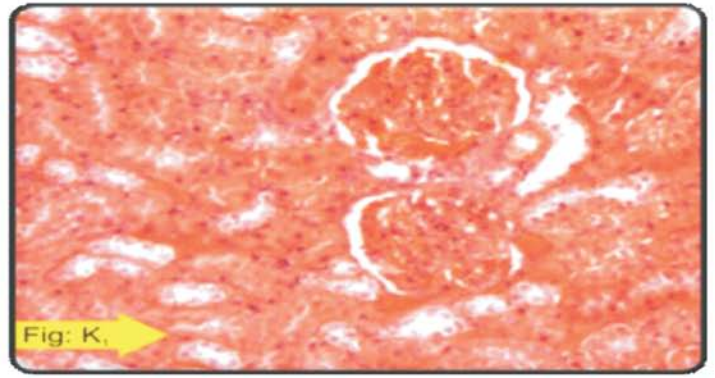
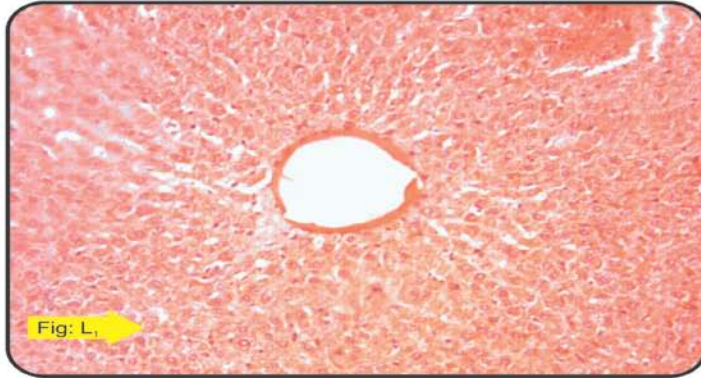
With 150 mg/kg body weight dose of crude extract the number of glomeruli undergoing shrinkage was more and more tubules were affected with hypertrophy. In some tubules the epithelial cells were

completely lost and, therefore, only large spaces were evident. Some atrophied glomeruli were also seen [Figure K₂]. 300 mg/kg body weight dose also showed similar effects but it was more intense. In the medullary region the tubules were better organized. The lumen was clear and the epithelial cells in some tubules showed hypertrophy [Figure K₃].

Discussion:

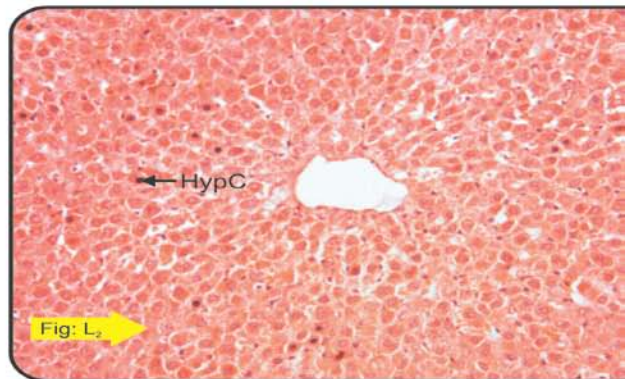
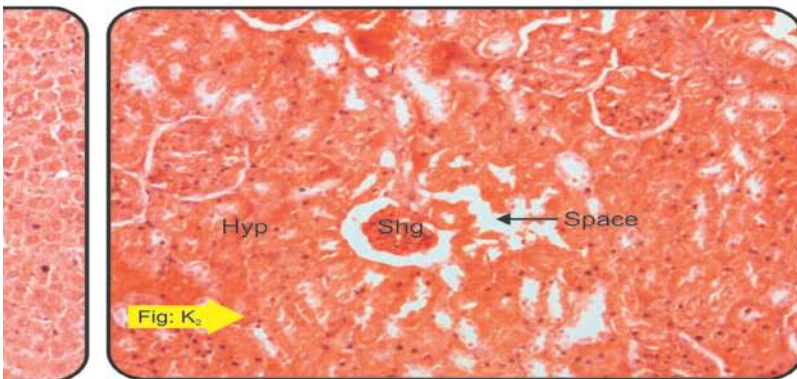
In the present study with both crude and ethanol extracts, toxic affects have been observed in liver. 150 and 300 mg/kg body weight doses showed variety of alteration in hepatocytes. Some hepatocytes were completely degenerated while others had degenerated nuclei and their cytoplasm was highly vacuolated. The effect was more pronounced with crude as compared to the ethanol extract. Effect of ethanol extract showed hypertrophy of hepatocytes with hyperchromatic nuclei in some regions. Coimbra and Leblond³ emphasized that hypertrophy may be correlated with glycogen depletion. Administration of latex of *Calotropis procera* in sheeps and goats induced severe pathological changes in the liver, kidneys, heart, lungs, brain and intestines. These were correlated with changes in the concentration of total protein, ammonia, bilirubin, sodium, potassium, calcium and creatinine in the serum. The concentrations of total lipids in the liver, heart and kidneys were raised⁶. Pahwa *et al.*,⁸ reported cloudy swelling of hepatocytes, inflammatory changes, Kupffer cell hyperplasia, cytoplasmic granulation, hepatocytolysis, compactness of lobular architecture, and occasional hemorrhage in the liver; cloudy swelling of convoluted tubular epithelium, inflammatory changes and hemorrhage in the kidney; erosion, increased mucus secretion, congestion and infiltration of lymphocytes in portions of the alimentary canal after intragastric application of bait consisting of latex of *Calotropis procera*. Hypertrophy of hepatocytes in the present study may be attributed to the interference in carbohydrate metabolism by the plant extracts. Number of Kupffer cells was increased around the sinusoids, which also indicates adverse affect on the liver. Some sinusoids/central vein in the present study also showed debris in the lumen. The question arises as to what in this debris and how it is accumulated in the central vein? The author is of the opinion that under the influences of the extracts the tunica intima of the central vein may be disrupted in some regions. Also it is possible that due to increase in Kupffer cell activity haemoconial debris may be formed which gets entangled in the intimal debris. Under toxic effects of the extracts it seems that flow pressure (blood pressure) in the sinusoids is considerably reduced as compared to the control which

is incapable of sweeping off the debris from the lumen in the present study has observed with the administration of both crude and ethanol extracts of *C. gigantea* glomerular shrinkage at 150 mg/kg doses, however, degree and number of glomeruli under going shrinkage increased with increased dose concentration. Some atrophied glomeruli were also observed. In some tubules the epithelial cells were completely lost.



Kidney (Control)

Liver (Control)



Kidney (150 mg extract)

Liver (150 mg extract)

Photomicrograph showing shrunken glomeruli, WBC infiltration and exfoliation of nuclei from the epithelium of uriniferous tubules.

Photomicrograph showing chord arrangement of hepatocytes with canaliculi. Hyperchromasia of some nuclei is seen.

REFERENCES:

1. Adak M. and J.K. Gupta (2006): Evaluation of anti-inflammatory activity of *Calotropis gigantea* (AKANDA) in various biological systems. *Nepal Med Coll J.*, 8(3):156-61.
2. Chitme H. R., M. Chandra and S. Kaushik (2004): Studies on anti-diarrhoeal activity of *Calotropis gigantea* R.Br. in experimental animals. *J Pharm Pharm Sci.*, 25;7(1):70-5.
3. Coimbra A. and C. P. Leblond, (1966): Sites of glycogen synthesis in rat liver cells as shown by electron microscope after administration of glucose H³. *J. Cell. Biol.*, 30,155.
4. Deshmukh P.T., J. Fernandes, A. Atul and E. Toppo (2009): Wound healing activity of *Calotropis gigantea* root bark in rats. *J Ethnopharmacol.*, 17;125(1):178-81.
5. Magos L. (1974): Renal tubular damage induced by mercuric chloride on male porton wistar rats. *The Brit. J. of Ex. Path.*, 55, No.6, 589.
6. Mahmoud O. M., S. E. I. Adam and G. Tartour (1979): The effects of *Calotropis procera* on small ruminants II. Effects of administration of the latex to sheep and goats. *Journal of Comparative pathology*, 89 (2), 251-263.
7. Morris Kupchan, S., John R. Knox, John E. Kelsey and J. A. Saenz Renauld (1964): Calotropin, a cytotoxic principle isolated from *Asclepias curassavica* L., *Science*, 146, 1685-1686.
8. Pahwa R. and V.C. Chatterjee (1988): The toxicity of Indian *Calotropis procera* RBr latex in the black rat, *Rattus rattus* Linn. *Vet Hum Toxicol.*, 30(4):305-8.
9. Pathak A.K. and A. Argal (2007): Analgesic activity of *Calotropis gigantea* flower. *Fitoterapia*. 78(1):40-2.
10. Ram Arjun, Duraisamy Arul Joseph, Selvakumar Balachandar, Vijay Pal Singh (2009): Medicinal plants from Siddha system of medicine useful for treating respiratory diseases. *International Journal of Pharmaceuticals Analysis*, Volume 1, Issue 2, 20-30.
11. Rathod N. R., I. Raghuvver, H. R. Chitme, and R. Chandra (2009): Free radical scavenging activity of *Calotropis gigantea* on streptozotocin-induced diabetic Rats. *Indian J Pharm Sci.*, (6): 615–621.
12. Tewari, P. V., P.V. Sharma, D.N. Prasad, C. Chaturvedi, and V.N. Pandey (1974): Pharmacological studies on saponins of *Costus speciosus* Sm. *Jour. Res. Ind. Med.*, 9, 1-5.
13. Wilson, L. *et al.* (1976): In: *Conferences on Cell Proliferation*, edited by R. Goldamn *et al.*, Cold Spring Harbour Vol.3, Book C, 1051.