



## Pyogenic Granuloma of the Larynx: A Case Report

Oguz Kadir Egilmez, Lokman Uzun, Sidika Seyma Ozkanli, M. Tayyar Kalcioğlu,

Istanbul Medeniyet University, School of Medicine Istanbul, Turkey

### ABSTRACT

Pyogenic granuloma (also known as lobular capillary hemangioma) is a benign and vascular lesion of the skin and mucous membranes that is frequently seen in the head and neck region. Although the etiology of the condition is still unknown, some conditions, such as trauma, poor oral hygiene, viral or fungal infections, and periodontal and gingival diseases, are considered to be related to the formation of pyogenic granuloma. The cheeks and the oral cavity are the major locations for pyogenic granuloma in the head and neck region, but larynx localization is also known, although rare. In this case report, we present a 47-year-old male patient with lobular capillary hemangioma of the left vocal fold and discuss the related literature.

### Introduction

Pyogenic granuloma is a benign lesion of the skin and mucous membranes. It has a diagnostic, lobular arrangement of capillaries, which is distinguished histologically from granulation tissue. In recent years, to emphasize this characteristic appearance, the term “lobular capillary hemangioma” has been introduced (1). This type of lesion is mostly seen in female patients between 20–40 years of age (2). The condition was first described in 1897 by Poncet and Dor (3). While the exact etiology is still unknown, trauma, poor oral hygiene, and gingival and periodontal diseases and infections are considered to be contributing factors (4). The head and neck region is the main location of pyogenic granulomas in the body, especially in the oral cavity; the most common site is the gingiva (5).

Larynx localization, although it has been reported previously, is extremely rare; it is clinically presented with a soft pedunculated lobular mass that grows rapidly and occasionally bleeds. A 47-year-old male patient with pyogenic granuloma of the left vocal fold was presented in this case report. Differential diagnosis, treatment options, and comparison with other cases in the literature are discussed in this paper.

### Case Report

A 47-year-old male patient came to our clinic with complaints of hoarseness and dysphonia. During the last two months, he had experienced voice fatigue and the sensation of a foreign body being lodged in his throat; he also complained about discomfort while swallowing liquids or solids. He had a history of an inguinal hernia operation (and so endotracheal intubation) under general anesthesia six years previously.

Upon physical examination, the oral cavity and dental conditions were normal. Videolaryngoscopy revealed a mass lesion located on the vocal process at the posterior part of the left vocal fold. There were some varicosities on the superior surface of the vocal folds that coursed toward the lesion on the left vocal fold.

Direct laryngoscopy was performed under general anesthesia; it revealed a multilobulated mass lesion (estimated 1x0.8 cm in size) originating from the posterior portion of the left vocal fold and obstructing the Rima glottis (Figure 1). The mass was excised surgically (Figure 2) and sent to the pathology laboratory. Histopathologic examination revealed ulceration on the surface of the lesion and ulcer floor containing fibrinoid necrosis.

Under the ulceration, vascular proliferation had been formed by a large number of capillary vessels, which were separated by fibrotic septae; mixed-type inflammatory cell infiltration was also seen under the light microscopy.

The lesion was therefore diagnosed as pyogenic granuloma (Figure 3). The postoperative course was uneventful; the patient was medicated with antibiotics and anti-reflux therapy and was discharged from the hospital. Recurrence of the lesion was visible (Figure-4) three months postoperatively, although it was very small compared to the initial mass; he is being followed with these findings.

### Discussion

Pyogenic granuloma is a vascular, benign lesion of mucous membranes and the skin. It is characterized by a lobular arrangement of capillaries, so that is also known as "lobular capillary hemangioma" (1). Trauma, poor oral hygiene, and gingival and periodontal diseases and infections are considered to be factors in the formation of this pathologic lesion (4). Some researchers think that this is a hyperproliferative vascular response to infective organisms of low virulence (6). Poncet and Dor, who first described this lesion in 1897, suggested that these organisms were fungi (3); in the nineteenth century, Hertzell believed that pyogenic granuloma was a localized bacterial infection (7).

In those years viral infection was also suggested but never reported. Recent studies about the etiology of pyogenic granuloma suggest trauma as the main etiologic factor (8). These researchers believe that after trauma to the mucous membrane, extensive granulation tissue is formed and healing is abnormal, thus leading to pyogenic granuloma (3).

In one case report, a female patient sustained a traumatic injury to her throat; the report found delayed presentation of pyogenic granuloma as a result of laryngeal trauma (9). Traumatic factors, which are vocal abuse such as coughing and persistent throat clearing, prolonged endotracheal intubation, previous surgeries, and gastric reflux, may play a role in the formation of this type of lesion. In our case report, the patient had a history of inguinal hernia operation (and so endotracheal intubation) six years previously, but videolaryngoscopic examination showed no signs of gastric reflux.

The majority (approximately two-thirds) of pyogenic granulomas in the body are located in the head and neck region. Partice et al. described the most frequent sites in the head and neck region, which were the cheek (28.8%), oral cavity (13.5%, especially gingiva), scalp (10.8%), forehead (9.9%), and eyelid and lips (both 9%) (7). Case reports in the literature also mention that the nasal septum is another location for pyogenic granuloma (10).

Larynx localization is very rare, and only a few cases have been reported. Rechtman and Armstrong reported a sixty-year-old male patient with pyogenic granuloma that arose from the posterior portion of the left vocal fold (11). In addition, Lai et al. reported a eighty-year-old woman with pyogenic granuloma located on a narrow pedicle arising from the right false vocal fold (12).

They also reported that this type of lesion is very rare, and is usually located in the cartilaginous portion. In 2001, Sataloff et al. presented a pyogenic granuloma case in which the lesion was based on a stalk attached to the right vocal process and posterior glottis (13). Yahirevitch et al. presented a case with a pyogenic granuloma arising from the vallecula; to the best of their knowledge, this case was the first report of pyogenic granuloma arising from the vallecular region (14).

Garrett et al. reported a pyogenic granuloma as a result of blunt laryngeal trauma, which had tethered off the superior aspect of the right arytenoid vocal process (9). In our patient, pyogenic granuloma was arising from the posterior portion of the left vocal fold and was attached with a pedicle to the vocal process, as has been described in a few other cases in the literature (Table 1).

Histologically, pyogenic granulomas differ from the granulation tissues because they have a lobular arrangement of capillaries in the deep portion of the lesion (1,6). To emphasize this phenomenon, the term "lobular capillary hemangioma" has recently been introduced (1). In our case, histopathologically, capillary lobular formation and endothelial and stromal elements with inflammatory infiltrates were revealed under the light microscopy.

Differential diagnosis is important for recognizing the pathology, and determining the appropriate treatment and prognosis of the disease. Some benign and malign lesions, such as hemangioma, hemangioendothelioma, angiofibroma, angiosarcoma, Kaposi sarcoma, Wegener's granuloma and Crohn's disease; and granulomatous infectious diseases such as tuberculosis and histoplasmosis, traumatic granuloma, carcinosarcoma, and verrucous and squamous cell carcinoma can be considered in the differential diagnoses of pyogenic granuloma of the larynx (9,15).

The vast majority of laryngeal lesions can be treated medically; some occasionally require surgical intervention. Medical treatment options are anti-reflux therapy, steroids, antibiotics, and voice therapy, as well as eliminating factors that cause irritation to the larynx (13). For pyogenic granuloma, however, observation, cauterization, and surgical excision are the treatment options (16). Granulomas can recur, and it has been reported that the recurrence rate was 16% with surgical excision, and 43.5% with cauterization alone (16). Lai and Sataloff also reported pyogenic granulomas that recurred despite intensive medical anti-reflux and voice therapy after surgical excision (12,13). We treated the granuloma arising from the left vocal fold by surgical excision under microscopy after direct laryngoscopy. Although it was very small compared to the initial lesion, recurrence of the lesion was seen in the period of three months postoperatively.

In conclusion, pyogenic granulomas are rarely located in the larynx. Symptoms may be mild or profound (such as respiratory distress), depending on the lesion's size. The main reasons for the formation of pyogenic granulomas are trauma and chronic irritation to the larynx. The mass lesions originating from the posterior glottis and pyogenic granuloma should be kept in mind in differential diagnoses.

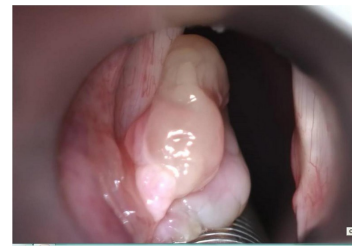

Figure 1: Direct laryngoscopic image of the mass lesion on the posterior part of the left vocal fold.

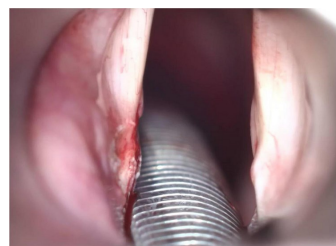


Figure 2: The image of the glottis after surgical excision of the mass

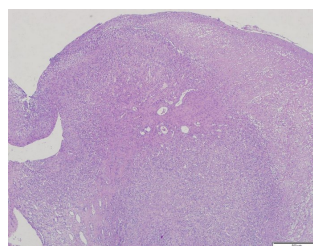


Figure 3: Histopathologic image of the lesion under light microscopy (Staining with H&E; 40x).

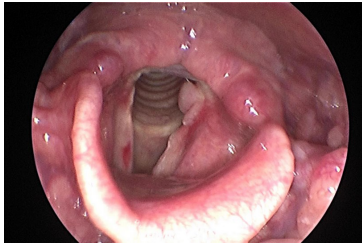


Figure 4: Videolaryngoscopic examination of the patient, postoperative third month.

Table I  
The main clinical features of the reported cases with pyogenic granuloma in the larynx

Author	Age of the patient	Location of the Lesion	Symptoms
Wang et al. <sup>1</sup>	Male, 27 years old	Vocal fold	Hoarseness, stridor
Chen et al. <sup>2</sup>	Male, 45 years old	Subglottic	Stridor, dysphagia
Wang et al. <sup>3</sup>	Male, 35 years old	Subglottic	Stridor, dysphagia
Wang et al. <sup>4</sup>	Male, 35 years old	Subglottic	Stridor, dysphagia
Wang et al. <sup>5</sup>	Male, 35 years old	Subglottic	Stridor, dysphagia
Wang et al. <sup>6</sup>	Male, 35 years old	Subglottic	Stridor, dysphagia
Wang et al. <sup>7</sup>	Male, 35 years old	Subglottic	Stridor, dysphagia
Wang et al. <sup>8</sup>	Male, 35 years old	Subglottic	Stridor, dysphagia
Wang et al. <sup>9</sup>	Male, 35 years old	Subglottic	Stridor, dysphagia
Wang et al. <sup>10</sup>	Male, 35 years old	Subglottic	Stridor, dysphagia

Table I: The main clinical features of the reported cases with pyogenic granuloma in the larynx

References:

1. Fechner RE, Cooper PH, Mills SE. Pyogenic granuloma of the larynx and trachea. A causal and pathologic misnomer for granulation tissue. Arch Otolaryngol 1981;107:30-32.
2. Nkanza NK, Hutt MS. Pyogenic granuloma: a study of 181 cases from Malawi. East Afr Med J 1981;58:318-323.
3. Kerr DA. Granuloma pyogenicum. Oral Surg Oral Med Oral Pathol 1951;4:158-176.
4. Vilmann A, Vilmann P, Vilmann H. Pyogenic granuloma: evaluation of oral conditions. Br J Oral Maxillofac Surg 1986;24:376-382.
5. Angelopoulos AP. Pyogenic granuloma of the oral cavity: statistical analysis of its clinical features. J Oral Surg 1971;29:840-847.
6. Karlıdağ T, Yalçın Ş, Akpolat N, et al. Pyogenic granuloma of the epiglottis: a case report. Türk Otolarengoloji Arşivi 2007; 45: 41-44.
7. Patrice SJ, Wiss K, Mulliken JB. Pyogenic granuloma (lobular capillary hemangioma): a clinicopathologic study of 178 cases. Pediatr Dermatol 1991;8:267-276.
8. Jafek BW, Wood RP 2nd, Dion M. Granuloma pyogenicum. Ear Nose Throat J 1977; 56:228-233.
9. Garrett MM, Lee WT. Obstructing pyogenic granuloma as a result of blunt laryngeal trauma. Otolaryngol Head Neck Surg 2007;136:489-490.

10. el-Sayed Y, al-Serhani A. Lobular capillary haemangioma (pyogenic granuloma) of the nose. *J Laryngol Otol* 1997;111:941-945.
11. Rechtman I, Armstrong PJ. Pyogenic granuloma of the vocal fold. *Anaesth Intensive Care* 1982;10:372.
12. Lai S, Kelleher K, Sataloff RT. Vocal fold granuloma: the "ball-valve" phenomenon. *Ear Nose Throat J* 2000;79:836.
13. Sataloff RT, Hawkshaw MJ. Multiple bilateral vocal fold cysts and recurrent pyogenic 'granuloma'. *Ear Nose Throat J* 2001;80:72.
14. Yakirevitch A, Fridman E, Bedrin L. Pyogenic granuloma arising from vallecula. *Otolaryngol Head Neck Surg* 2006;134:175-176.
15. Wenig BM, Heffner DK. Contact ulcers of the larynx. A reacquaintance with the pathology of an often underdiagnosed entity. *Arch Pathol Lab Med* 1990;114:825-828.
16. Mills SE, Cooper PH, Fechner RE. Lobular capillary hemangioma: the underlying lesion of pyogenic granuloma. A study of 73 cases from the oral and nasal mucous membranes. *Am J Surg Pathol* 1980;4:470-479.