



Proptosis due to otolaryngology causes a study

*Balasubramanian Thiagarajan *Kamakshi Kothandaraman

* Stanley Medical College

Abstract:

Proximity of orbit to nose and paranasal sinuses makes it rather vulnerable to insults due to otolaryngological causes. The medial wall of orbit (Lamina papyracea) is rather paper thin and it happens to form the lateral wall of anterior ethmoid air cells. Infections / tumors involving paranasal sinuses can involve orbit also causing proptosis. The aim of the article is to study the common otolaryngological causes of proptosis in our Institution during 2009 – 2012.

Introduction:

Proptosis is defined as abnormal protrusion of eyeball. It has in fact been used interchangeably with exophthalmos. Purists consider exophthalmos as proptosis with lid lag (since it is commonly associated with Grave's disease). According to Epstein in Proptosis the globe protrudes out by 18 mm or less and exophthalmos is globe protrusion of more than 18 mm¹. Henderson prefers reserving the term exophthalmos to proptosis caused by endocrine causes². Proptosis should be differentiated from exorbitism which is caused by decrease in the volume of orbit causing the orbital contents to protrude anteriorly. In exorbitism proptosis is always anterior.

Anatomy of orbit and its relationships with paranasal sinuses:

Orbit is related to paranasal sinuses in two ways:

1. Anatomically by its location and by
2. 2. venous drainage (They both share the same venous drainage).

The paranasal sinuses surround the orbit from 11 o'clock position superiorly to 6 o'clock position inferiorly.

The orbit is pyramidal shaped formed by several bones. The superior wall of the orbit is shared by the floor of the frontal sinus, the floor of the orbit is shared by the roof of the maxillary sinus, the medial wall of the orbit is shared by the lateral wall of ethmoidal sinus. These shared bones are really thin enabling infections to travel from either direction. The medial wall of the orbit is so thin that it is termed as lamina papyracea.

Anatomical uniqueness of orbit:

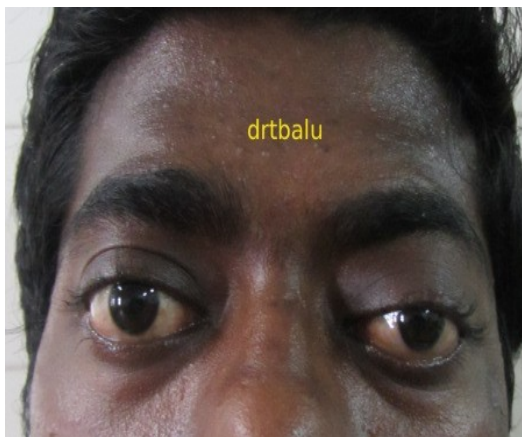
1. It is a closed space

2. It is devoid of lymphatics
3. Intraorbital pressure may increase to a limit of breaking point
4. Main constituents of orbit are muscle and fat
5. Extraocular muscles are fine voluntary muscles with excessive interstitial tissue

Peculiarities of venous drainage in this area: The veins draining this area are peculiar in the following aspects:

1. The whole venous system in this area is devoid of valves, consequently a two way pathway of infection between the orbit, nasal cavity and paranasal sinuses become a reality.
2. The superior ophthalmic vein connects the facial veins to the cavernous sinus thus causing infections from face to spread to the cavernous sinus.
3. One branch of the inferior ophthalmic vein connects the orbit with that of the veins of pterygoid plexus and the other branch connects the orbit with that of the cavernous sinus.

The approximate volume of the orbital cavity is about 30 ml. Since the contents of the orbit are within a rigid confines of the orbital walls any disease process within the orbit or adjacent region has a tendency to displace the orbital contents forwards, this displacement of the globe is known as the proptosis. Other symptoms of globe displacement include diplopia, and visual loss.



Exophthalmos due to Graves disease



Proptosis due to frontoethmoidal mucocele

Methodology:

All patients who present to otolaryngology department outpatient during the period 2009 – 2012 were taken up for study. Bilateral proptosis (exophthalmos) was excluded from our study.

Type of study: Retrospective

Aim:

1. To ascertain various otolaryngological causes of proptosis
2. To ascertain the various otolaryngological clinical presentations of these patients with proptosis

All these patients under went radiological imaging to prove the exact cause for proptosis. Ophthalmologist opinion was sought for all these patients to rule out ophthalmological cause for proptosis.

Results:

Number of patients presented to Otolaryngology department with proptosis: 62

Male – 46

Female – 16

Fungal sinusitis – 12

Fronto ethmoidal mucocele – 8

Maxillary sinus malignant tumors – 11

Ethmoidal malignancy – 2

Nasal polyposis – 9

Fibrous dysplasia⁵ – 6

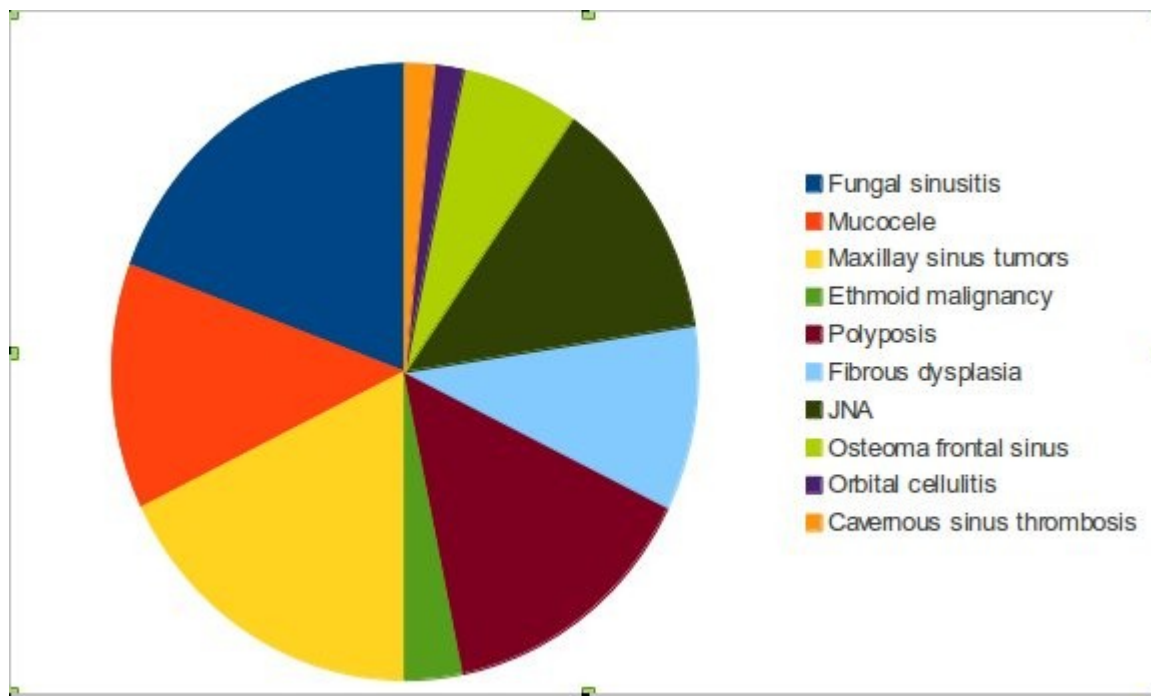
Juvenile nasopharyngeal angiofibroma – 8

Osteoma frontal sinus⁴ – 4

Orbital cellulitis – 1

Cavernous sinus thrombosis – 1

This study reveals fungal sinusitis to be commonest otolaryngological cause for proptosis. Fungal sinusitis were initially considered as ethmoidal polyposis causing proptosis³.



Graph showing various otolaryngological causes of proptosis

Discussion:

This study reveals changing trends in the causative factors of proptosis⁶ (This reference illustrates JNA to be the common otolaryngological cause for proptosis). Fungal sinusitis is gradually emerging as one of the common otolaryngological causes of proptosis.

The mnemonic VEIN is helpful in remembering the causes of proptosis.

V - Vascular causes

E - Endocrine causes

I - Inflammation and infective causes

N - Neoplastic causes

Imaging studies:

CT scan and MRI scan of the orbit may prove beneficial in diagnosing the cause for proptosis. The presence of fat in the orbit serves as an inherent contrast medium for the study. 3 mm cuts are ideal for the study of orbit. Ultrasound studies using either A or B mode may help in rapid diagnosis of the cause for proptosis.

Vascular causes of proptosis:

Vascular causes of proptosis can be classified into arterial and venous causes. Venous causes are due to the formation of dilated veins known as varices. Patients with these varices give a classic history of positional proptosis (proptosis varying with positions) or proptosis being induced by valsalva maneuver. In patients with long standing varices there is also an associated orbital fat atrophy leading on to a transient stage of enophthalmos. In these patients a valsalva maneuver may reveal proptosis. CT scan performed with jugular venous compression or during a valsalva maneuver may prove diagnostic. Surgical intervention in these patients may prove disastrous, hence observation and treatment of complications is advisable.

In dural venous sinus fistula the shunt is low flow in type and proptosis is insidious in onset, high index of suspicion is necessary in diagnosing these patients.

Carotid cavernous fistula (high flow shunts) may arise as a result of trauma or spontaneously. These patients have subjective bruits, proptosis, chemosis and vision loss. The conjunctival vessels become arteriolised assuming a cock screw pattern. A fistula of spontaneous occurrence has a better chance of spontaneous resolution, but in intractable cases the shunt must be closed with a balloon or carotid artery ligation.

Endocrine causes of proptosis: are the most common cause of exophthalmos. The diagnosis is fairly simple because it is invariably associated with lid signs like lid lag. The major endocrine cause for proptosis is thyrotoxicosis. This condition is also known as Graves disease.

Characteristic features of endocrine causes of proptosis:

1. Presence of lid lag / lid retraction
2. Presence of temporal flare in the upper eyelid
3. Presence of orbital congestion

CT scan of the orbit show enlarged extra ocular muscles, there may also be a bulging of orbital septum due to protrusion of fat. This is pathognomonic of Grave's disease. TSH estimation show elevated levels in the serum.

Inflammatory causes of proptosis: In inflammatory proptosis the lesion could be either an idiopathic inflammatory orbital pseudotumor, or due to specific orbital inflammation. Proptosis in these

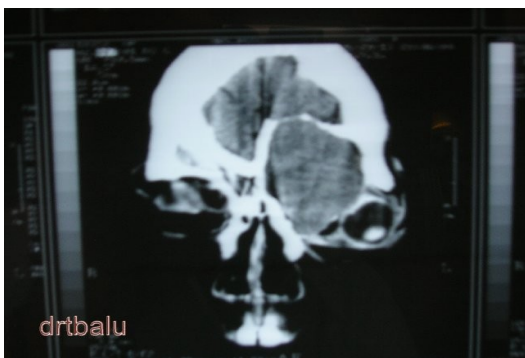patients appear suddenly and acutely. These patients are invariably toxic and febrile. Myositis of extra ocular muscles may cause pain when eyes are being moved. There may also be associated acute dacryo adenitis. There may also be peri optic neuritis causing blindness. Orbital inflammation, perioptic neuritis and dacryo adenitis are highly responsive to oral prednisolone.

Inflammations involving the paranasal sinuses may involve the orbit causing proptosis. The intervening walls between the medial orbital wall and the ethmoidal sinuses is paper thin (lamina papyracea) which can be easily breached by infections from the ethmoidal sinuses causing spread to the orbit. In proptosis caused by ethmoidal sinus pathology the eye is pushed laterally, where as proptosis due to maxillary sinus pathology causes deviation of the eye upwards and outwards. In frontal sinus pathology the eye is deviated downwards and outwards. Commonest sinus inflammatory cause for proptosis is the formation of mucocèles in the paranasal sinuses. This commonly occur in the fronto ethmoidal regions.

Neoplastic causes of proptosis: Neoplasms involving orbit may cause proptosis. Here the eye is pushed directly forwards. This type of proptosis is known as axial proptosis. Tumors involving the optic nerve can cause axial proptosis. These patients have pain free disease. The only exception to lack of pain is patients with adenocystic carcinoma of lacrimal gland. These patients have excessive pain because the tumor infiltrates the nerves.

Neoplastic lesions involving the paranasal sinuses can also cause proptosis. The common benign tumor involving the sinuses causing proptosis are:

1. Inverted papilloma
2. Fungal infections involving the paranasal sinuses
3. Mucocèles involving the paranasal sinuses
4. Fibrous dysplasia of the maxilla
5. Osteomas involving the frontal and ethmoidal sinuses
6. Juvenile nasopharyngeal angiofibroma



Coronal CT scan showing proptosis due to frontoethmoidal mucocèle

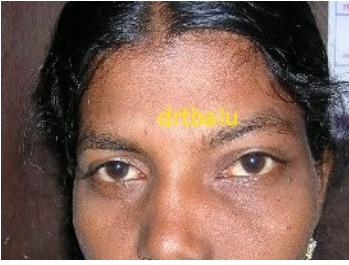

Image showing proptosis due to fibrous dysplasia



Figure showing proptosis due to frontoethmoidal mucocele

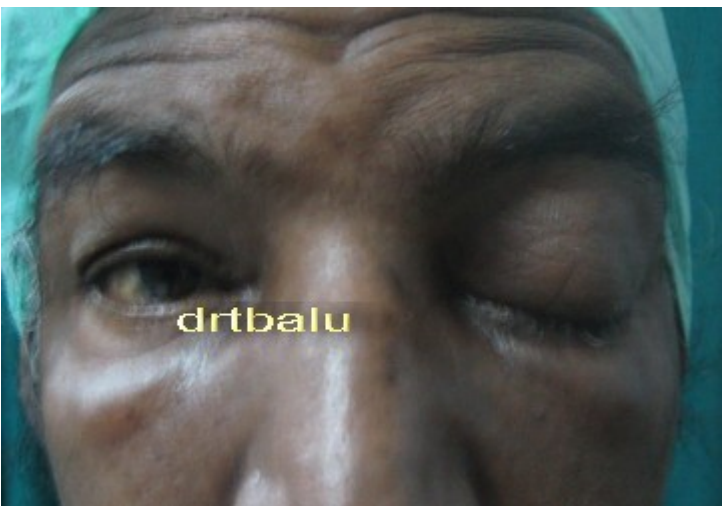

Figure showing proptosis due to fungal sinusitis

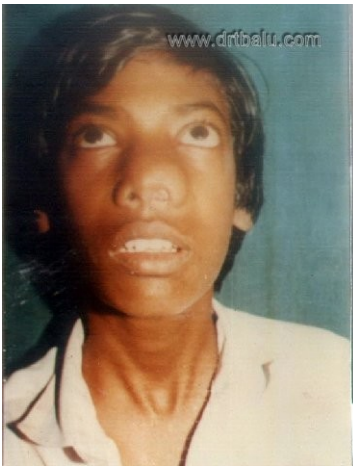

Figure showing proptosis due to JNA

Measuring proptosis using exophthalmometer:

Hertel mirror exophthalmometers are used to measure the degree of protrusion of the eyeball. The distance between the lateral orbital rim and corneal apex is used as an index for measuring proptosis. Under normal conditions this distance is roughly 18 mm, there may be individual and racial variations.

Procedure: The examiner is seated in front of the patient at the eye level of the patient. The exophthalmometer is then positioned with the blue arched support at the temporal lateral orbital walls. The instrument is maneuvered using both hands and firmly propped first against the right-hand orbital wall on the temporal side (which should be felt against the lowest part of the support point). The movable part is then set in such a way that the left-hand orbital wall lies against the lowest part of the arched support. The distance between the lateral orbital walls can then be read from the upper side of the scale; this distance can be noted for future reference. The examiner asks the patient to look straight ahead with eyelids wide open. The examiner measures for proptosis in each eye separately by looking into the mirror (which has a millimeter scale marked on it) with one eye and moving the head horizontally until the red fixation line is at 22mm. The examiner can now determine the position of the corneal apex of the patient from the millimeter reading.

Conclusion:

This study reveals that fungal sinusitis is emerging as a common otolaryngological cause for proptosis. A large sample study will throw more light on this problem. In all the previous studies reviewed Malignant tumors involving nose and sinuses was cited to be the most common otolaryngological cause for proptosis.

References:

1. Epstein O, Perkin D, Cookson J, deBono DP. Clinical Examination. 3Rd ed. Mosby; 2003.
2. Henderson JW. Orbital Tumors. 3Rd ed. New York: Raven Press; 1994.
3. Calcaterra TC, Trapp KT, Unilateral proptosis Otolaryngologic Clinics of North America 1988; 21: 53- 63.
4. Atallah N and Jay M.M.. (1981) Osteomas of the paranasal sinuses. Journal of Laryngology and Otology 95, 291-304.
5. THIAGARAJAN, Balasubramanian. Fibrous dysplasia of Faciomaxillary region case reports and review of literature. Otolaryngology online journal, US, v. 1, n. 1.5, oct. 2012. ISSN 2250- 0359. Available at: <<http://jorl.net/index.php/jorl/article/view/9>>. Date accessed: 24 Nov. 2012.
6. PROPTOSIS THROUGH EYES OF E.N.T. SURGEON Vikas Sinha, Deepak Bhardwaj, Ajay George, Rizwan A. Memon Indian Journal of Otolaryngology and Head and Neck Surgery Vol. 57, No. 3, July-September 2005