



## Nasal Septal Schwannoma – A Rare Cause of Unilateral Nasal Obstruction

S. H. Gawarle<sup>1</sup>, Subhro Ganguly<sup>1</sup>, P. N. Keche<sup>1</sup>, A. R. Buche<sup>1</sup>, S. Bhat<sup>1</sup>, N. A. Davange<sup>1</sup>, R. Ravi<sup>2</sup>

<sup>1</sup>Shri Vasantrao Naik Government Medical College, Yavatmal, Maharashtra, India

<sup>2</sup>Consultant Pathologist, Nagpur, Maharashtra, India

### ABSTRACT

Schwannoma is a benign neoplasm arising from the Schwann cells in the nerve sheath. According to the previous literature 25-45% of all Schwannomas arise in the head and neck region and only less than 4% occur in the sino-nasal tract. Schwannoma of nasal septum is an extremely rare presentation of this well understood pathology with only few cases reported in the literature. We present a case of 70 year old woman with two year long history of left sided nasal obstruction, rhinorrhoea and hyposmia. After imaging and histopathology, diagnosis of nasal septal Schwannoma was confirmed.

The massive nasal mass, extending up to oropharynx, was completely removed by endoscopic approach with no recurrence at the end of ten months follow-up. The diagnosis of a unilateral nasal mass provides an opportunity to discuss the wide array of possible causes of nasal and septal masses as well as various presentation of Schwannoma. To the best of our knowledge such a massive septal Schwannoma extending beyond the confines of nasal cavity up to oropharynx has not yet been reported in the literature.

## Introduction

Schwannomas also known as Neurilemmomas or Neurinomas or Perineural Fibroblastomas are benign, slow growing, encapsulated tumors originating in the neural crests derived from Schwann cells. First described by Verocay (1908) as Neurinomas and later by Stout (1935) as Neurilemmomas, these tumors arise from the Schwann cells of any myelinated nerve including cranial nerves (except olfactory and optic nerve), peripheral nerves, sympathetic and parasympathetic nerves [1,2]. They are predominantly found in the head and neck region comprising 25-45% of all Schwannomas [3]. In the head and neck region most frequent site affected is the Internal Acoustic Meatus in the form of Vestibular Schwannoma with other sites being scalp, face, oral cavity, pharynx, larynx, trachea, parotid gland, external auditory canal and middle ear[4,5]. There is no racial and gender predilection and it can occur at any age[6,7].

Sino-nasal Schwannomas are very rare accounting for only less than 4% of all head and neck Schwannomas[8,9]. Ethmoid sinus is the most commonly affected area followed by maxillary sinus, nasal cavity and sphenoid sinus [2,10].

Schwannomas of the nasal septum is exceptionally rare[11,12]. A case of Schwannoma of nasal septum was first described by Bogdasian and Stout in 1943[11].

Clinically patients usually present with non-specific nasal symptoms like unilateral nasal obstruction, rhinorrhoea, hyposmia/anosmia, headache and epistaxis[13]. CT scan usually shows hypodense areas in the centre with peripheral rim of contrast enhancement[14].

Histopathology is considered as the most confirmatory diagnostic tool which reveals typical patterns characterized by Antoni A and Antoni B areas[15]. Local recurrence is not reported yet in case of complete excision of benign Schwannoma[16]. Malignant Schwannomas occur in 2% cases.

We discuss the clinical presentation and management protocol of a patient diagnosed as benign Schwannoma of nasal septum.

## Case Report

A 70 year old woman visited our centre with a history of left sided nasal obstruction gradually progressive over a period of two years. She also complained of recurrent rhinitis, hyposmia, hyponasal voice and occasional headache. There was no history of epistaxis, facial swelling or facial pain. She denied having any medical problems or addiction. There was no significant past or family history and there was no prior history of trauma, surgery or irradiation. Her general and systemic examination findings were unremarkable. On anterior rhinoscopy a single polypoidal smooth surfaced pinkish mass was seen filling the left nasal cavity reaching up to vestibule deviating the septum to the right side (Fig. 1).

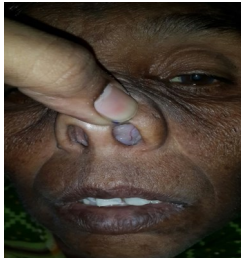


Figure 1

The mass was firm, sensitive to touch and pain, not bleeding on touch. Examination of oral cavity revealed bilateral palatal bulge and a globular mass hanging in the oropharynx (Fig. 2).

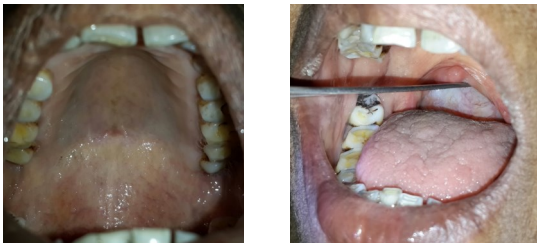

Fig 2

Rest of the ear, nose and throat examination were normal and there was no significant cervical lymphadenopathy. Posterior rhinoscopy revealed a large globular mass hanging in the oropharynx. Rigid nasal endoscopy was performed and the scope could not be negotiated in the left nasal cavity. On the contralateral side there was gross deviation of nasal septum to right and the mass was seen in the nasopharynx blocking both the choanae.

Complete blood count, biochemistry parameters and coagulation profile were all within normal limits. Contrast enhanced CT scan of PNS was done to know the extent and nature of the mass. It showed a homogenous soft tissue lesion measuring 85x35x21 mm in left nasal cavity extending into nasopharynx and oropharynx. The mass was seen arising from the left side of the septum. The septum was markedly deviated to the right side. The mass completely obliterated the turbinates and osteo-meatal complex on the left side. All these seemed to be secondary changes due to mass effect. The turbinates and osteo-meatal unit on right side were normal. There were soft tissue density noted in the maxillary, ethmoid and sphenoid sinuses on both sides which were compatible with pan-sinusitis. No bony erosion was seen on CT scan. On contrast study, there was irregular mild enhancement (Fig. 3).

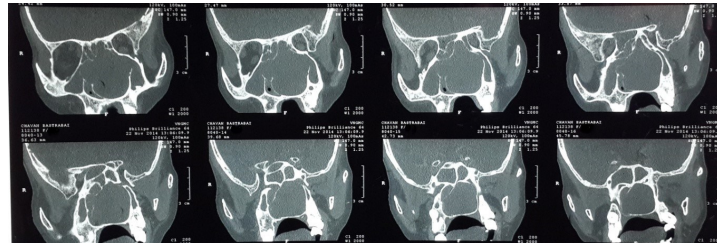
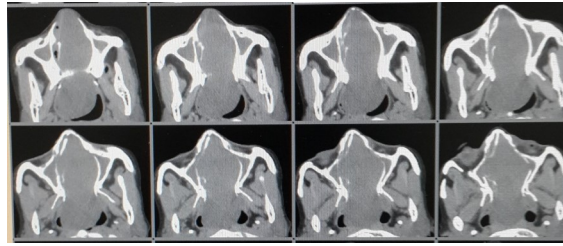


Figure 3

Subsequently, punch biopsy was taken and sent for histopathological examination which revealed spindle shaped cells with slender elongated nuclei arranged in fascicles and bundles intersecting each other with marked fibroblastic proliferation. Cellular atypia and mitotic figures were absent (Fig. 4).

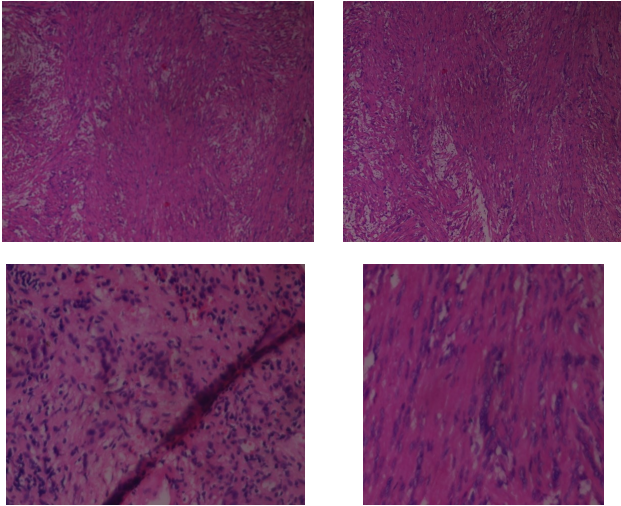


Figure 4

A provisional diagnosis of nasal Schwannoma was made and patient was posted for endoscopic excision under general anaesthesia after taking informed consent.

En bloc excision of the mass was not possible due to its huge size. The mass was seen attached to the postero-superior part of the left side of nasal septum. The nasal part of the mass was removed completely by piecemeal approach with a cuff of septal perichondrium by a regular endoscopic sinus surgical procedure. The nasopharyngeal and oropharyngeal part of the mass were removed transorally (Fig. 5).

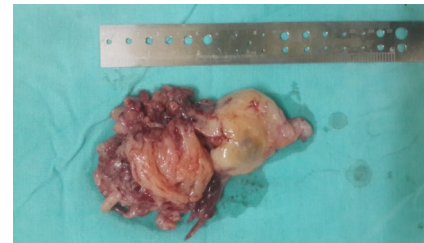
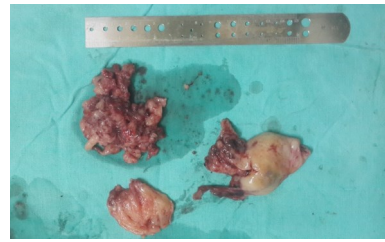


Figure 5

The turbinates were found to be atrophied on the left side. Although there was mucosal thickening and fluid retention in all the sinuses, which were cleared eventually, the mucosal lining of the sinuses was not invaded by the tumor. The operative procedure and the post operative recovery periods were uneventful.

Histopathology of the excised specimen showed alternating hypercellular Antoni A areas with typical Verocay Bodies and hypocellular myxoid Antoni B areas. There was no evidence of nuclear atypia or mitotic activity thus ruling out malignant Schwannoma. The tumor cells showed strong and diffuse immunoreactivity for S100 protein and negativity for Cytokeratin, Vimentin and CD34. The diagnosis of Schwannoma was retained. A regular follow-up for a period of ten months showed no signs of recurrence.

## Discussion

Schwannoma is a benign, solitary, slow growing, polypoidal neurogenic tumor. The histogenesis of this neoplasm was controversial as previously the term Schwannoma was reserved either for Neurofibroma or Neurilemmoma. It was first described in 1908 by Verocay who believed that these tumors arise from the nerve sheath and he termed them Neurinoma. Later in 1935, Stout confirmed the origin of the tumor and coined the term Neurilemmoma [1,2].

Schwannomas arise from Schwann cells of the nerve sheath of peripheral nerves, autonomic nerves, and cranial nerves (except Olfactory Nerve and Optic Nerve as they do not contain Schwann cells). In head and neck region most commonly affected nerve is eighth cranial nerve giving rise to Vestibular Schwannoma [4,5].

Almost half (15-45%) of all the Schwannomas arise in head and neck region. While lateral cervical region and mouth are more commonly affected areas, Schwannomas of sino-nasal tract is not a frequent presentation as only 4% of all head and neck Schwannomas are found in nose and para-nasal sinuses. Most preferential site for sino-nasal Schwannoma is ethmoid sinus with others being maxillary sinus, nasal cavity and sphenoid sinus [17,18]. Localization of nasal Schwannoma to the septum is extremely unusual as not many cases have been reported previously [12,19-21].

Typically Schwannomas arise from large peripheral nerves such as eighth cranial nerve, Vagus nerve, sympathetic trunk. However, it can be rarely seen in smaller nerves of head and neck region where it becomes very difficult to locate the nerve of origin even intra-operatively.

Nasal Schwannomas are thought to be arising from the ophthalmic and maxillary branches of the Trigeminal nerve or autonomic ganglion. Septal Schwannomas are presumed to be originating from the somatosensory nerves of the nasal septum (mostly nasopalatine and nasociliary nerve branches [2,12,19,22,23]).

In this location the tumor has been reported in patients aged between 6 year and 78 years. There is no gender or racial predilection [8]. There is apparently no preferential side for septal Schwannoma as well. Nasal Schwannomas are usually solitary lesions unless they are associated with Neurofibromatosis type 2 [12]. As these are slow growing tumor, mostly they remain asymptomatic unless they attain large size. They rarely undergo malignant transformation [16].

Clinically patients present with a variety of non-specific symptoms which are mostly due to the mass effect. Most common symptom is nasal obstruction followed by epistaxis with other symptoms being rhinorrhea, hyposmia or anosmia, headache, facial pain and facial swelling. Epistaxis is usually associated with nose and ethmoid neoplasm whereas facial pain and swelling is more commonly found in lesions of maxillary sinus. There are no distinctive attributes to be noted on examination of the mass [24-26].

Differential diagnosis of unilateral nasal mass include inflammatory polyp, papilloma, neurofibroma, leiomyoma, meningioma, angiofibroma, lobular capillary haemangioma, olfactory neuroblastoma. Such a wide variety of possible pathologies underlines the difficulty in diagnosis of sino-nasal lesions by history and clinical examination alone. Therefore, it is a good practice to perform imaging and biopsy in each and every such cases before finalising the course of management[13,22].

CT scan study of PNS offers a lot in lesions of this region as it gives a wholesome idea about the extent of the tumor, size of the tumor and involvement or erosion of any adjacent bony structures. It also helps the surgeon to draw a roadmap for surgery depending on the areas and structures involved. Contrast study should also be performed as some of the Schwannomas are very vascular[2]. As benign Schwannoma can erode bone due to pressure effect, erosion of bone alone is not a criteria for malignancy[14]. It is not always possible to determine the site of origin of the tumor radiologically. Typical CT scan of Schwannoma reveals a central hypodense area with peripheral contrast enhancement due to peripheral neovascularisation[14]. Septal Schwannomas usually cause deviation of the septum to the opposite side. Large tumor and long standing cases often cause atrophy or erosion of turbinates. Pan-sinusitis can be found if the tumor causes obstruction of the osteo-meatal complex thus obscuring the sinus drainage pathways [8,12,24,27,28]. Trans-septal extension to opposite nasal cavity was reported in one case[24]. Till date no cases of septal Schwannoma extending to skull base have been reported[29].

Macroscopically, Schwannomas appear as gelatinous or cystic, well encapsulated mass with smooth surfaces. Microscopically, Schwannomas are classically divided into two major histological patterns – Antoni A and Antoni B. This distinction is purely of academic interest and has no clinical importance. These two patterns can be present in different proportions and independently of each other. Antoni A area exhibits an organised cellular stroma with elongated spindle cells. On cross-section this spindle cells provide a palisading pattern of nuclei around a central mass of cytoplasm called a Verocay body. Antoni B area, which is thought to be a degenerative form of Antoni A, is composed of disorganised loose myxoid stroma with spindle cells[8,30].

The S-100 protein is present in the astrocytes, oligodendrocytes, giant cells and Schwann cells of the peripheral nerves. It shows more positivity in Antoni A areas. If a Schwannoma does not exhibit typical histological appearances, immunohistochemical staining showing positivity for S-100 will help clinch the diagnosis[30,31].

Ideal management of Schwannoma is wide local excision of the tumor mass with an approach which provides adequate exposure as the tumor is chemo-resistant and radio-resistant[22,24]. Endonasal endoscopic approach far supersedes traditional approaches like lateral rhinotomy and degloving techniques.

Not only it is cosmetically and functionally superior and associated with less morbidities, it provides a magnified view which helps in better delineation of the area of the tumor attachment and preservation of the important adjacent structures as well[8]. No recurrences have been reported as yet in case of complete excision of the tumor although regular follow-up is of utmost importance as local recurrences have been reported in case of incomplete removal of tumor.

## References

1. Stout AP(1935) The peripheral manifestations of the specific nerve sheath tumour (neurilemmoma). *Am J Cancer* 24:751-796
2. Batsakis JG (1974) *Tumours of the Head and Neck, Clinical and Pathological Consideration*. Baltimore, MD, Williams & Wilkins, pp 231-249
3. Conley JJ (1955) Neurogenic tumours in the neck. *Arch Otolaryngology* 61: 167-180
4. Donnelly MJ, AlSader MH, Blayney AW (1992) Benign nasal Schwannoma. *J Laryngol Otol* ; 106:1011-1015.
5. Niemczyk K, Vaneecloo FM, Houcke-Lecomte M. et al. (2000) Correlation between Ki67 index and some clinical aspects of acoustic neuromas (vestibular Schwannomas). *Otolaryngol Head Neck Surg* ; 123:779-783.
6. Buob D, Wacrenier A, Chevalier D. (2003) Schwannoma of the Sinonasal Tract: A Clinicopathologic and Immunohistochemical Study of 5 Cases *Archives of Pathology and Laboratory Medicine*: Vol. 127, No. 9, pp. 1196-1199.
7. Yusuf H, Fajemisin OS, McWilliam LJ (1989) Neurilemmoma involving the maxillary sinus: a case report. *Br J Oral Maxillofac Surg* 27:506–511
8. Berlucchi M, Piazza C, Blanzuoli L, Battaglia G, Nicolai P. (2000) Schwannoma of the nasal septum: a case report with review of the literature. *Eur Arch Otorhinolaryngol* 257:402–405.



9. Shugar JM, Som PM, Biller HF, Som ML, Krespi YP (1981) Peripheral nerve sheath tumors of the paranasal sinuses. *Head Neck Surg* 4:72–76
10. Calcaterra TC, Rich R, Ward PW.( 1974) Neurilemmoma of the sphenoid sinus. *Arch. Otolaryngol*;100 :383–385.
11. Bogdasarian RM, Stout AP (1943) Neurilemmoma of the nasal septum. *Arch Otolaryngol* 38:62–64
12. Butugan O, Schuster GS, de Almeida ER, Miniti A (1993) Schwannoma of the nasal septum. Apropos of 2 cases. *Rev Laryngol Otol Rhinol* 114:33–36
13. Kaufman SM, Conrad LP (1976) Schwannoma presenting as a nasal polyp. *Laryngoscope* 86:595–597
14. Younis RT, Gross CW, Lazar RH (1991) Schwannomas of the paranasal sinuses. Case report and clinicopathologic analysis. *Arch Otolaryngol Head Neck Surg* 117:677–680
15. Yang TL, Hsu MC, Liu CM.( 2001) Nasal Schwannoma: a case report and clinicopathologic analysis. *Rhinology*; 39:169–72.
16. Guzzo M, Ferraro L, Ibba T, Quattrone P, Bianchi R, Rezzonico S, Scaramellini G.( 2009) Schwannoma in the parotid gland. Experience at our institute and review of the literature. *J Exp Clin Oncol*; 95:846–851.
17. Hillstrom RP, Zarbo RJ, Jacobs JR.( 1990) Nerve sheath tumors of the paranasal sinuses: electron microscopy and histopathologic diagnosis. *Otolaryngol Head Neck Surg* ; 102:257–263.
18. Donnelly MJ, AlSader MH, Blayney AW.( 1992) Benign nasal Schwannoma. *J Laryngol Otol*; 106: 1011–1015.
19. Rajagopal S, Kaushik V, Irion K, Herd ME, Bhatnagar RK.( 2006) Schwannoma of the nasal septum. *Br J Radiol* 79:e16–e18.
20. Wang LF, Tai CF, Chai CY, Ho KY, Kuo WR. ( 2004) Schwannoma of the nasal septum: a case report. *Kaohsiung J Med Sci*;20:142–145.
21. Pagella F, Giourgos G, Matti E, Colombo A. ( 2009) An asymptomatic Schwannoma of the nasal septum: report of a unique case. *Ear Nose Throat J.*; 88:1264–1265.
22. Pasic TR, Makielski K (1990) Nasal Schwannoma. *Otolaryngol Head Neck Surg* 103:943–946
23. Robitaille Y, Seemayer TA, El Deiry A (1975) Peripheral nerve tumors involving paranasal sinuses: a case report and review of the literature. *Cancer* 35:1254–1258
24. Oi H, Watanabe Y, Shojaku H, et al.( 1993) Nasal septal neurinoma. *Acta Otolaryngol. (Stockh). (suppl. 504)*;151–154.
25. Enion DS, Enkins A, Miles JB, et al.( 1991) Intracranial extension of a naso-ethmoid Schwannoma. *J. Laryngol. Otol.* ;105: 578–581.
26. Higo R, Yamasoba T, Kikuchi S.( 1993) Nasal neurinoma: case report and review of literature. *Auris Nasus Larynx* ;20: 297–301.
27. Thomas JN.( 1977) Massive Schwannoma arising from the nasal septum. *J Laryngol Otol*; 91: 63–68.
28. Wada A, Matsuda H, Matsuoka K, Kawano T, Furukawa S, Tsukuda M.( 2001) A case of Schwannoma of nasal septum. *Auris Nasus Larynx*; 28: 173–175.

29. Zovickian J, Barba D, Alksne JF.( 1986) Intranasal Schwannoma with extension into the intracranial compartment: case report. *Neurosurgery*; 19: 813–815.
30. Donnelly MJ, al-Sader MH, Blayney AW.( 1992) Benign nasal Schwannoma. *J Laryngol Otol.*; 106 (11):1011-1015.
31. Kragh LV, Soule EH, Masson JK (1960) Benign and malignant neurilemmomas of the head and neck. *Surg Gynecol Obstet* 111:211–218