



Kashima's Posterior cordectomy using coablator our experience.

Balasubramanian Thiagarajan Vrinda Balakrishnan Nair

Stanley Medical College

Abstract:

Aim:

To study the effectiveness of coblation technology in performing Kashima's procedure for bilateral abductor vocal fold paralysis.

Methodology:

Managing patients with bilateral vocal fold abductor paralysis is rather tricky one. It calls for delicate balance between airway and phonation. Various endolaryngeal techniques have been used to manage this problem. Here the authors describe their experience with posterior cordectomy using coablator. This study includes 10 patients who presented with stridor following bilateral abductor paralysis. All our patients were on tracheostomy tubes. They were very anxious with the tube and wanted decannulation done. All of these patients were operated by the same senior surgeon. These patients were managed with posterior cordotomy using coblation. Laryngeal wands were used in all these patients. These patients underwent spigoting of their tracheostomy tube on the first post operative day. Decannulation was completed on the third post operative day. Early decannulation was made possible because there was negligible soft tissue oedema as these patients underwent coblation procedure.

Observation:

On discharge all of them had a good voice and adequate airway.

These patients were able to climb two flights of stairs without discomfort.

Although the causes of bilateral abductor paralysis of vocal cords are multifactorial post traumatic paralysis formed a large majority of our patients (8 who developed bilateral vocal fold paralysis following total thyroidectomy).

Introduction:

Bilateral vocal fold immobility is a rather common bilateral vocal fold immobility syndrome. This is commonly caused due to damage to both recurrent laryngeal nerves. Embryology has made the course of recurrent laryngeal nerves (nerve of the 6th branchial arch) rather complicated and highly variable.

Causes of bilateral abductor vocal fold paralysis include ¹:

1. Surgical (Commonly following post thyroidectomy) close to 59% in some studies.
2. Intubation about 25%
3. Trauma 2%
4. Neurological disorders 15%
5. Extra laryngeal malignancies 5-17% ²

Clinical features of bilateral abductor paralysis of vocal folds:

1. Stridor due to airway compromise
2. Near normal voice

Dyspnoea may be varying in degree depending on ³:

1. Amount of glottic chink
2. Arytenoid body mass
3. Presence / absence of comorbidity
4. Physical activity

10% of these patients need no intervention. Some of them could decompensate making them dyspnoeic ⁴.

For centuries tracheostomy has been the gold standard in the management of bilateral abductor vocal fold paralysis. All the procedures are compared with tracheostomy to ascertain their efficacy. Introduction of Kleinsasser suspension laryngoscope revolutionised endolaryngeal surgical procedures and treatment of bilateral abductor vocal fold paralysis.

Results:

Total number of patients taken up for study = 10

Female = 7

Male = 3

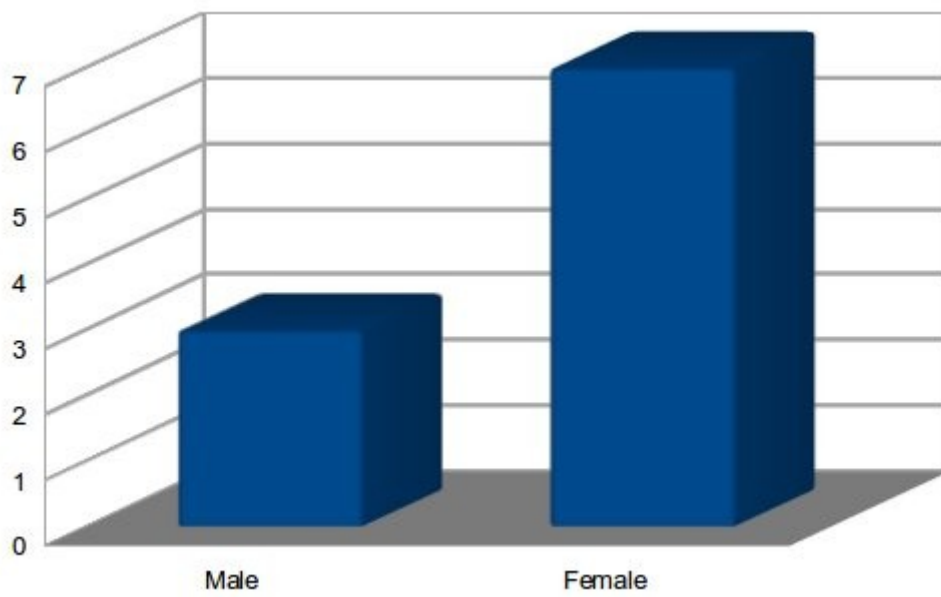


Figure showing sex distribution among patients with bilateral abductor vocal fold paralysis

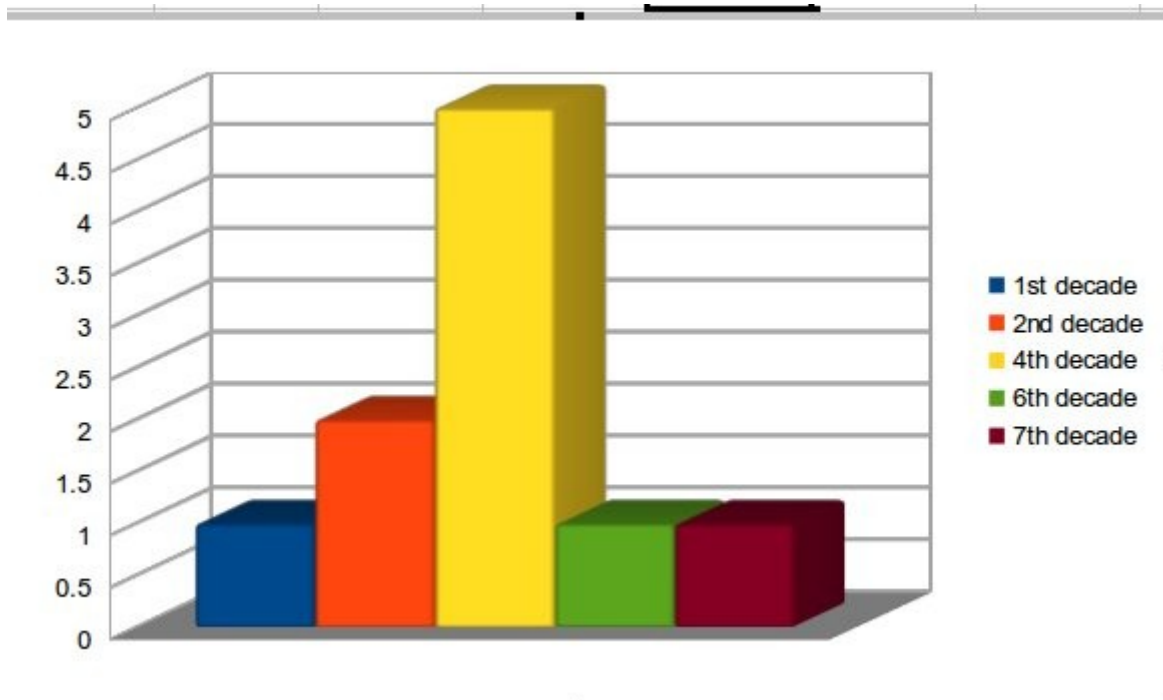


Figure showing age distribution of patients with bilateral abductor paralysis

Majority of our patients were in the 4th decade of life.

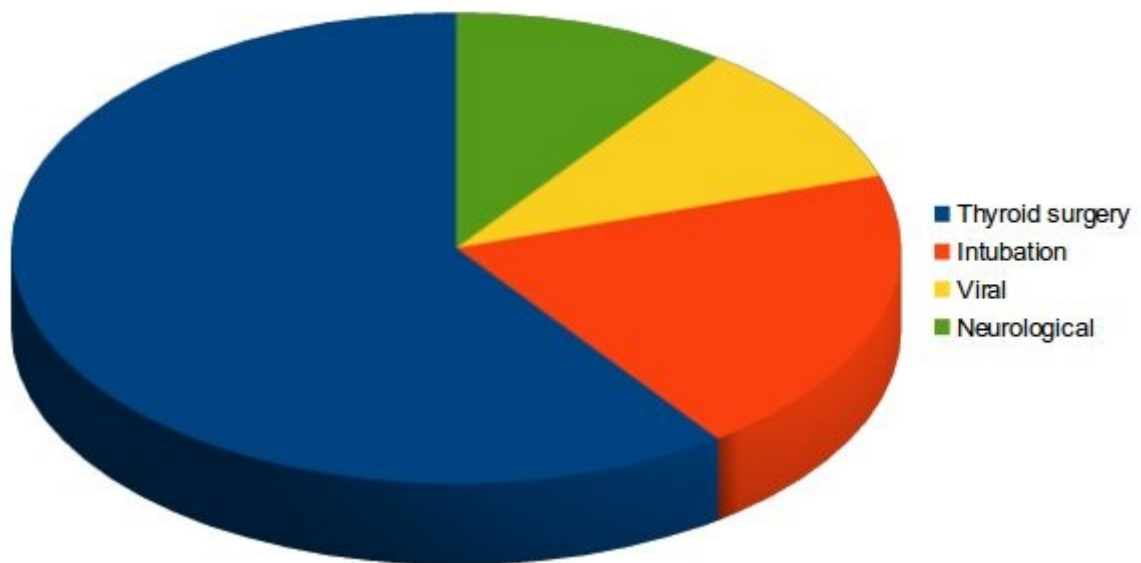


Figure showing the various etiological factors that caused bilateral abductor paralysis in our study group

Iatrogenic causes of bilateral abductor vocal fold paralysis was common in our study group. Almost all of these patients underwent total thyroidectomy.

Patients in this study were on tracheostomy for periods ranging from 2 – 10 years. None of them tolerated spigotting of the tracheostomy tube. Decanulation procedure was attempted in all of these patients but failed.

Procedure:

The surgical procedure introduced by Dennis and Kashima in 1989 revolutionised the management of bilateral abductor vocal fold paralysis. This technique is based on resection of soft tissues and transection of conus elasticus. A “C” Shaped wedge of posterior vocal fold is excised beginning from the free border and extending to about 4mm laterally. Basic rationale in this procedure is the release of tension of the glottic sphincter rather than actual removal of glottic tissue. If airway is not adequate then the same procedure can be carried out on the opposite side also. Reker and Rudert modified the original Kashima procedure which involved complementary resection in the body of lateral thyroarytenoid muscle anteriorly from the initial triangular incision. This produced a larger airway with good voice. 9 of our patients underwent the classic Kashima procedure while one patient underwent Reker's procedure⁶.

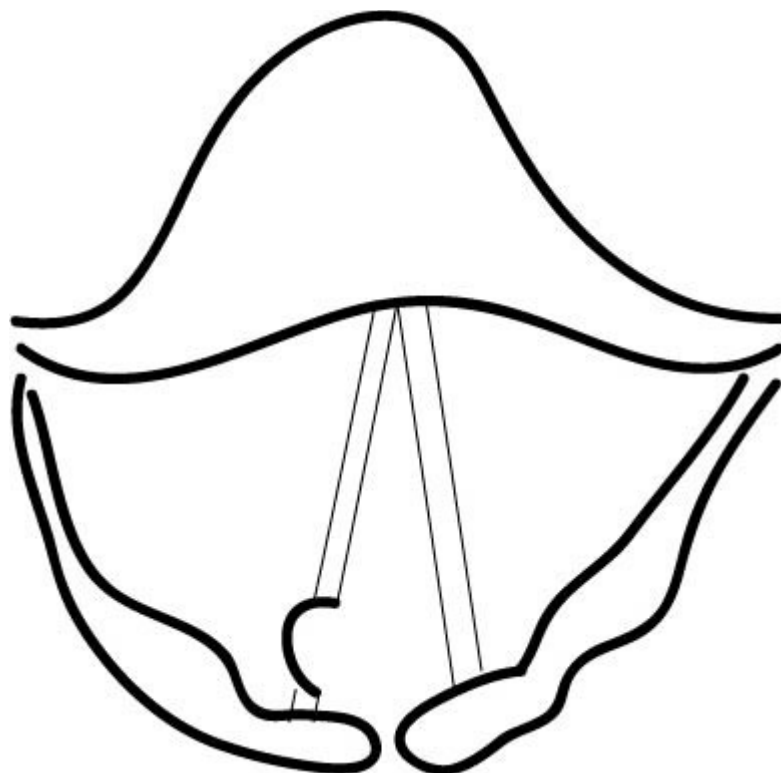


Diagram showing the site of resection in Kashima's procedure

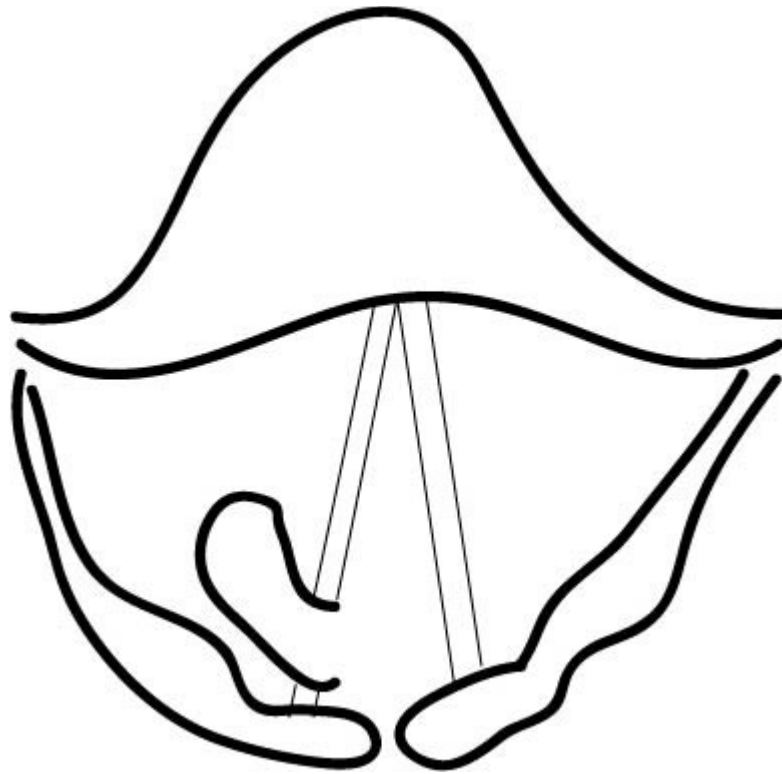


Figure showing Recker's modification of Kashima's procedure

Since all our patients were on tracheostomy, the same stoma was used for intubation for anesthesia purposes. Under general anesthesia Kleinsasser laryngoscope is used to expose the laryngeal inlet. Coblator was used for this procedure. Laryngeal wand was used to resect the posterior portion of the vocal fold.

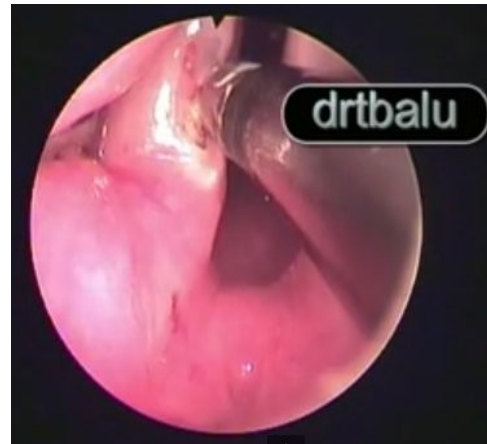
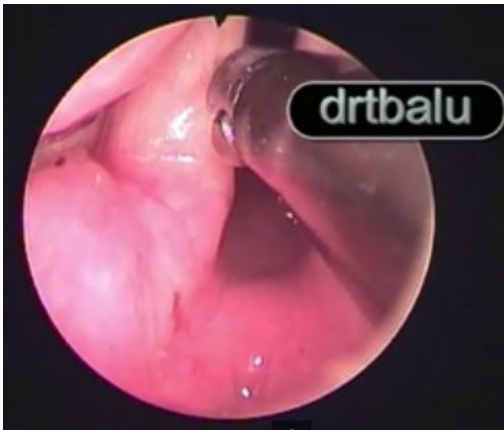


Figure showing Kashima's surgery using laryngeal wand

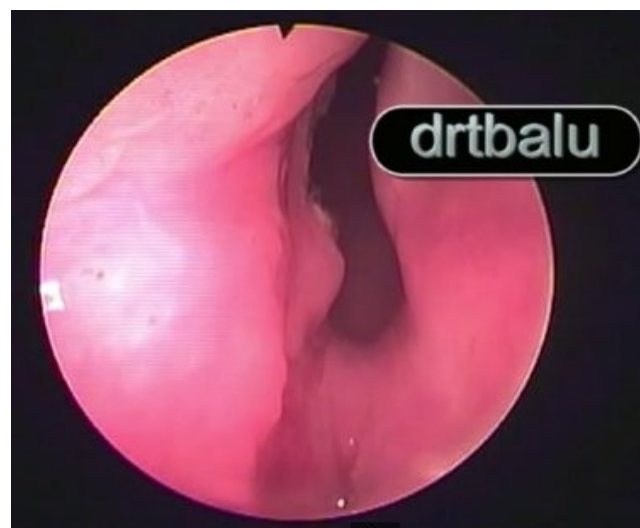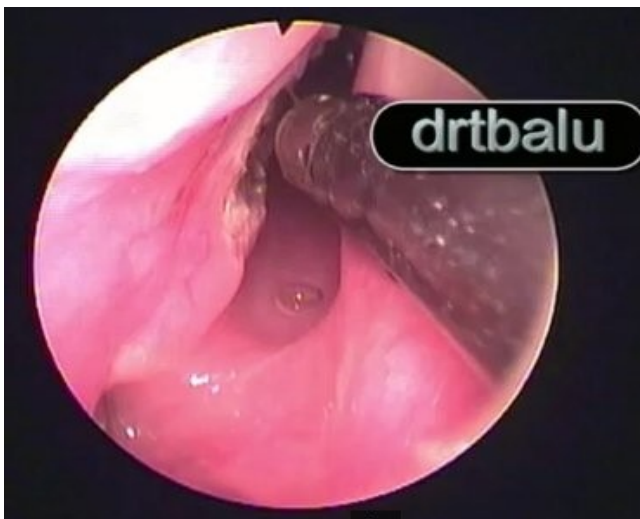


Figure showing Kashima's surgery after completion of the procedure

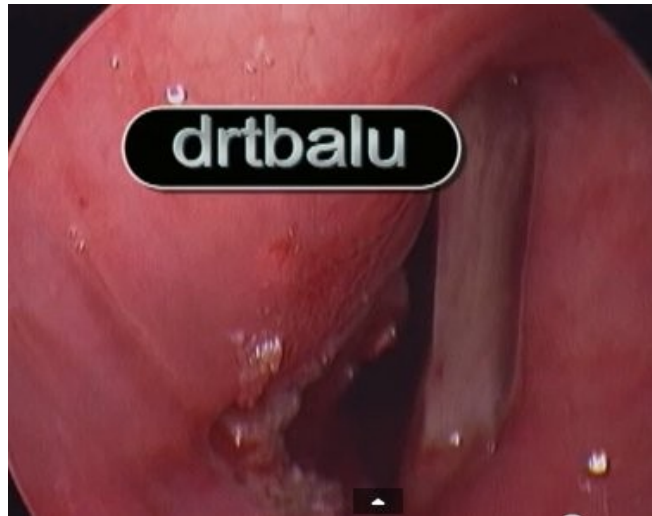


Figure showing Reker's modification of kashima's procedure

Conclusion:

Performing Kashima's procedure using coblation technology is really promising. Advantages of this procedure include:

1. Blood less ablation
2. Precise ablation of tissue
3. No collateral damage to adjacent tissue
4. No oedema of tissues around larynx
5. Early decannulation is possible

References:

1. Benninger MS, Gillen JB, Altman JS (1998) Changing etiology of vocal fold immobility. *Laryngoscope* 108:1346–1350
2. Leon X, Venegas MP, Orus C, Quer M, Maranillo E, Sanudo JR (2001) Inmovilidad glotica: estudio retrospectivo de 299 casos. *Acta Otorrinolaringol Esp* 52:486–492
3. Kleinsasser O, Nolte E (1981) Endolaryngeale Arytaenoidektomie und submuköse partielle Chordektomie bei bilateralen Stimmlippenlähmungen. *Laryngorhinootologie* 60:397–401
4. Sessions DG, Ogura JH, Heeneman H (1976) Surgical management of bilateral vocal cord paralysis. *Laryngoscope* 86:559–566
5. Dennis DP, Kashima H. Carvon dioxide laser posterior cordotomy for treatment of bilateral vocal cord paralysis. *Ann Otol Rhinol Laryngol.* 1989, 98:930-934.
6. Reker U, Rudert H (1998) Die modiWzierte posteriore Chordectomie nach Dennis und Kashima bei der Behandlung beidseitiger Rekurrensparesen. *Laryngorhinootologie* 77:213–218