



Fracture frontal bone and its management

Balasubramanian Thiagarajan

Stanley Medical College

Abstract:

Fractures involving frontal bone are rather uncommon. Injuries to this bone is rather critical because of its proximity to brain. This article attempts to discuss this topic with focus its prevalence, its causes and various treatment modalities available. Three crucial areas need to be addressed. They include anterior table, posterior table and frontal sinus outflow tract. Posterior table fractures are usually associated with anterior table fractures and CSF leak. Hence these patients should be treated as head injury cases

Introduction:

Fractures involving frontal bone is rather rare because of its protected location ¹. It is basically protected from trauma by the prominence formed by the nasal pyramid. Incidence of fractures involving this area ranges between 5-15% ³. Fractures involving this bone is considered to be rather dangerous because of its proximity to brain as well as due to the cosmetic defects it can produce. The proximity of this bone to the orbit and naso frontal duct doesn't help matters either. Fractures involving this area if not treated promptly can lead to ²:

1. Meningitis
2. Mucopyocele
3. Encephalitis
4. Cerebral abscess

It should be borne in mind that all cases of fractures involving frontal bone should be considered as a potential head injury and should be managed similarly because of its close proximity to the brain.

Causes of frontal sinus injuries:

1. Road traffic accident
2. Assault
3. Industrial accidents
4. Recreational accidents

Classification of frontal bone:

Anterior table fracture

1. With / without displacement
2. With / without outflow tract injury

Posterior table fracture commonly occurs in combination with anterior table fracture

1. With / without displacement
2. With / without dural injury / CSF leak
3. With / without outflow tract injury

Displacement is considered to be present if it is about the width of one table of the frontal bone.

Anatomy of frontal sinus:

Among the para nasal sinuses this sinus shows the maximum variations. In fact variations are so immense that it can safely be stated that frontal sinuses are unique in each and every individual. It may be absent in 5 % of individuals. It is more or less shaped like a L. Drainage channel of frontal sinus is highly variable.

Posterior wall: corresponds to the anterior wall of the anterior cranial fossa.

Floor: is formed by the upper part of the orbits. Frontal sinus appear very late in life. In fact they are not seen in skull films before the age of 6.

The sinus drains into the anterior part of the middle meatus through the fronto nasal duct.

Frontal outflow tract shows conglomeration of air cells.

Types of frontal sinus air cells include:

I – Type I frontal cell (a single air cell above agger nasi)

II – Type II frontal cell (a series of air cells above agger nasi but below the orbital roof)

III – Type III frontal cell (this cell extends into the frontal sinus but is contiguous with agger nasi cell)

IV – Type IV frontal cell lies completely within the frontal sinus

Materials and methods:

In this study all patients with Faciomaxillary trauma presented at Stanley Medical College Hospital during the 4 year period from 2009 – 2012 were taken.

Inclusion criteria:

All patients with Faciomaxillary injuries.

Exclusion criteria:

Nil

Total number of patients enrolled: 128

All of them had Faciomaxillary injuries.

Number of patients with frontal bone fracture: 12

Total number of patients with Faciomaxillary trauma	Number of patients with frontal bone fracture
128	12

Anterior table fractures – 10

Posterior table fractures – 2

All 12 patients were males.

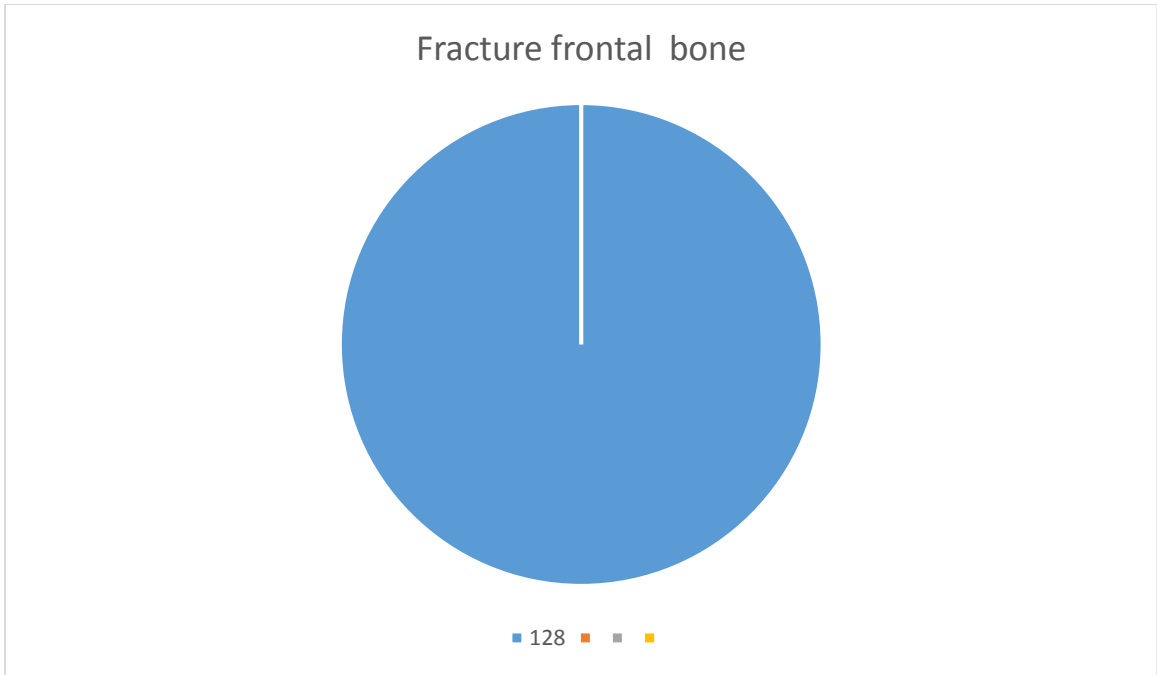
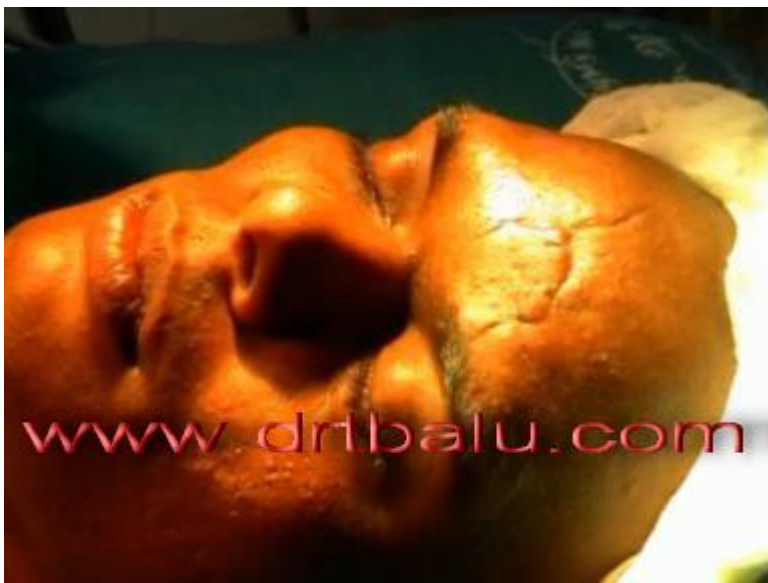

Chart illustrating patients with fracture frontal bone among those with facio maxillary trauma



Clinical photograph of a patient with fracture anterior table of frontal sinus

Common causes of fractures involving frontal bones:

1. Road traffic accident
2. Assault
3. Industrial accidents
4. Recreational accidents

A study of our patients reveal that 8 of them suffered injury due to road traffic accident and 4 patients suffered due to assault.

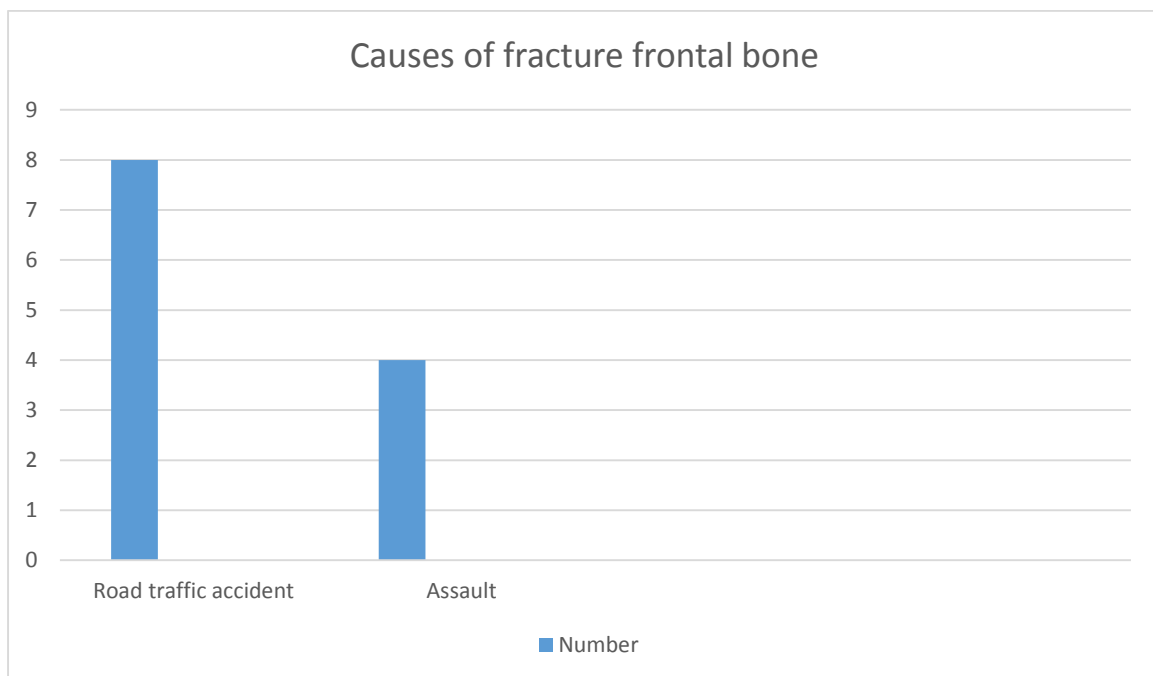


Chart depicting the common causes of fracture frontal bone in our study

Clinical presenting features:

These include:

1. Cosmetic defect
2. Headache
3. CSF leak (in patients with posterior table fractures)

Treatment goals:

1. Protection of intracranial structures
2. Control of CSF leak
3. Prevention of late complications like secondary mucocoeles
4. Deformity correction

Assessment of patient with injury to frontal sinus:

1. All suspected patients should undergo a complete ophthalmic examination to rule out injury to the eye.
2. All these patients must undergo CT scan of brain and skull for complete evaluation
3. The patient's consciousness should be monitored carefully to rule out intracranial complications
4. Other associated injuries must be looked for because the force necessary to cause fracture of frontal bone is enormous.

Anterior table fractures:

This is caused by low energy trauma. Commonly this fracture is isolated non displaced fracture. If there is no displacement then observation alone is sufficient.

If it is associated with displacement of fractured fragments then open reduction with internal fixation is the way to proceed.

If there is associated damage to frontal outflow tract then frontal sinus obliteration is advised along with open reduction and internal fixation. Reconstruction of outflow tract is a difficult procedure and is unpredictable. One other way to tackle this problem is observation and medical management followed by endoscopic sinus surgery in future is need arises.

When open reduction with internal fixation is performed care should be taken to avoid entrapment of mucosa⁴ within the bone fragments as this would lead to mucocoele formation at a later date. Accurate identification of frontal out flow tract injuries are rather difficult to identify in routine CT imaging. Periodical CT scans can be performed to look for evidence of frontal sinus outflow tract obstruction. Frontal trephining can be performed

and endoscope can be introduced via the trephine to observe for evidence of outflow tract obstruction.

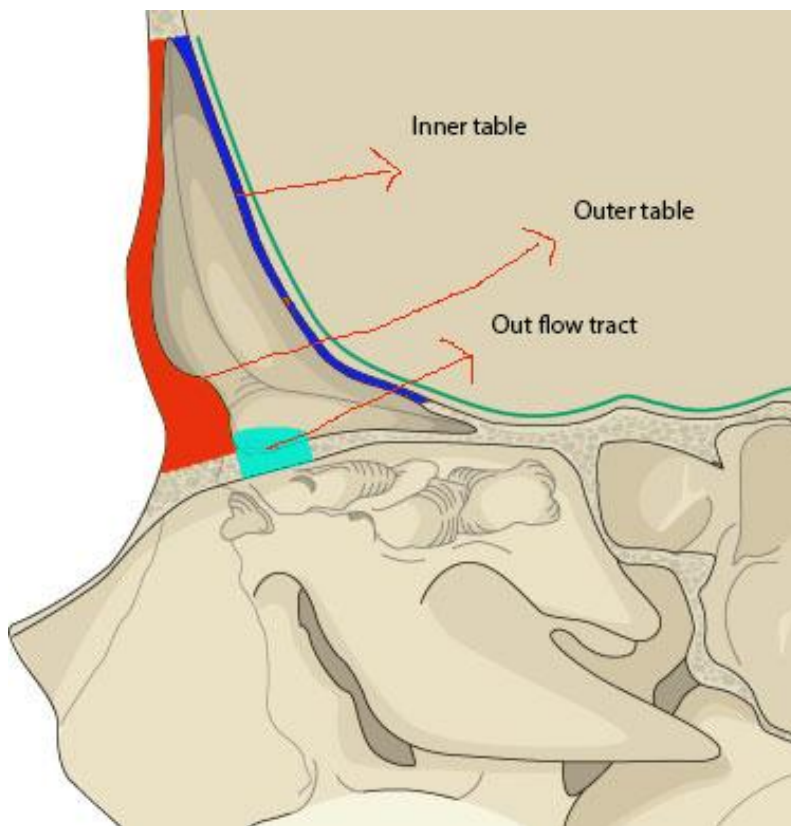
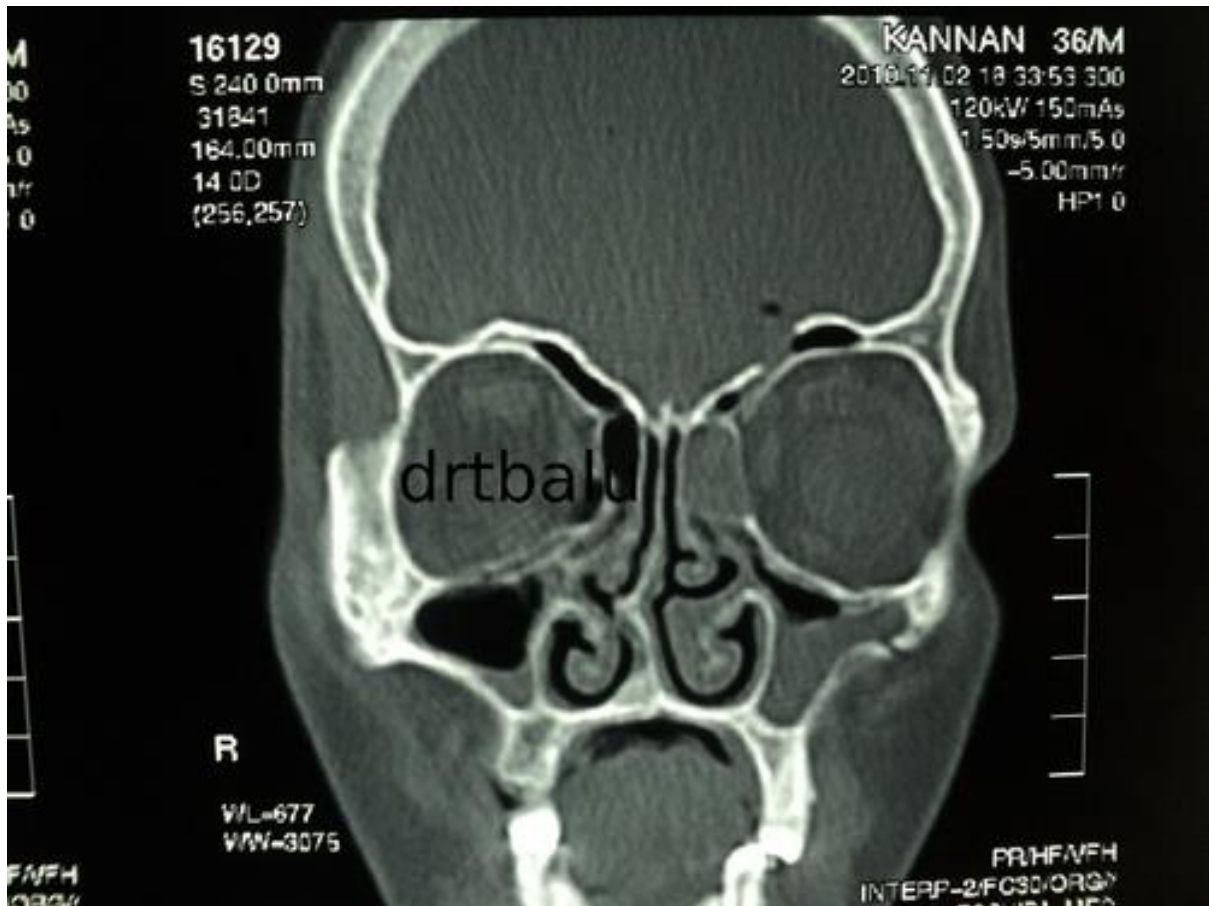


Diagram illustrating various parameters that should be focussed on during the management of frontal bone fractures

Three vital areas that should be addressed while managing fractures of frontal bone:

1. Anterior table

2. Posterior table
3. Frontal sinus outflow tract



Coronal CT scan of nose and sinuses showing fracture involving posterior table of frontal sinus

Management:

Our patients who needed open reduction and internal fixation were managed with

1. Supraciliary approach
2. Bicoronal approach⁵

Since one of the two patients who needed open reduction and internal fixation had a scar in the supraciliary area the incision was sited in the supraciliary region.

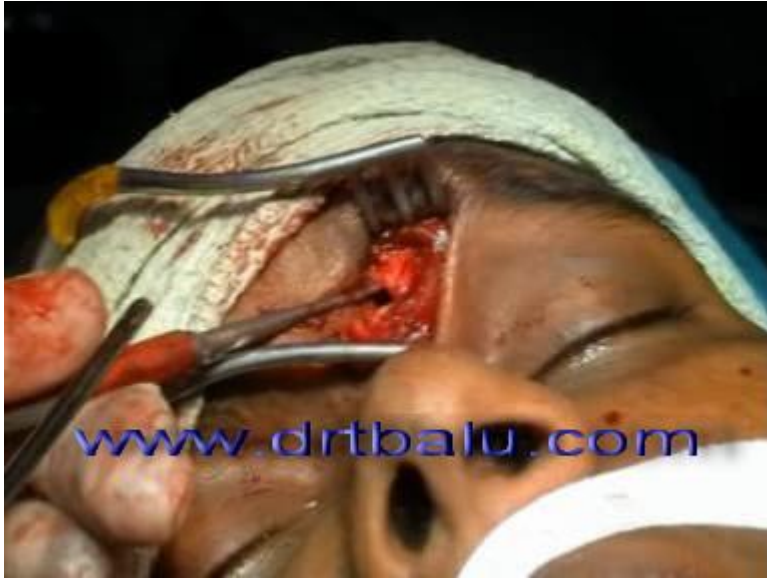

Image showing fractured fragment of outer table being exposed via supraciliary incision

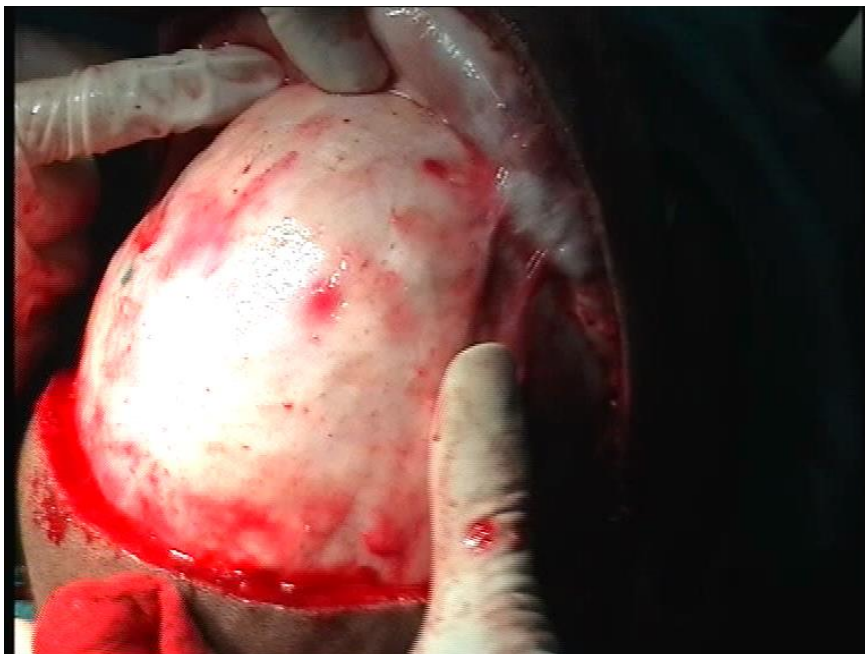


Image showing Bicoronal flap being raised

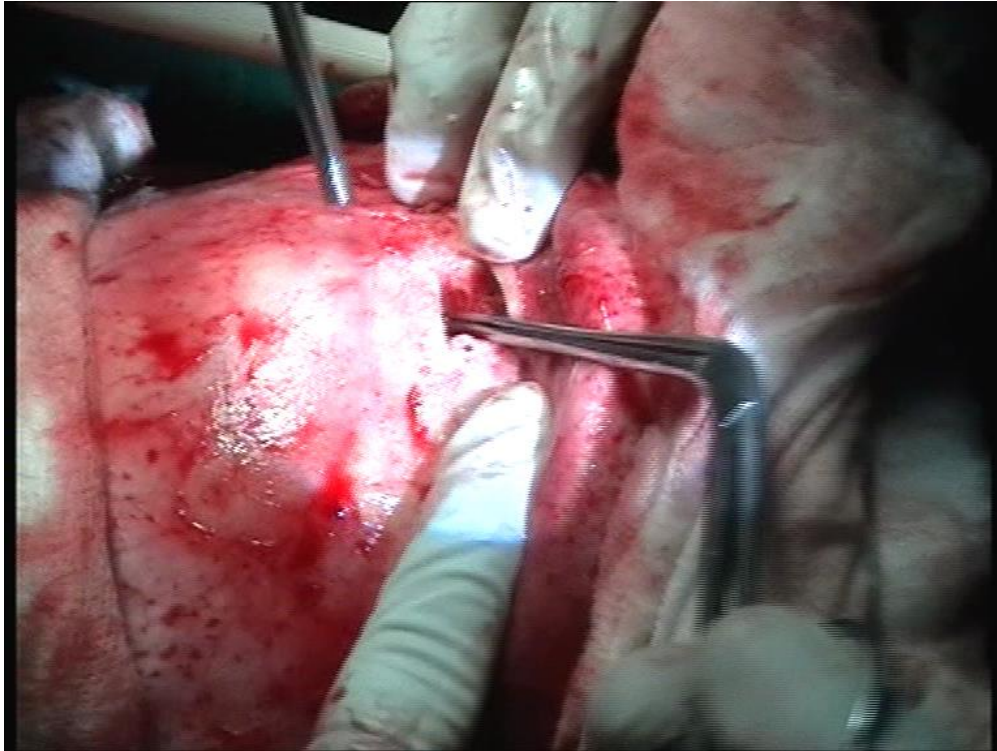

Image showing frontal sinus being entered via anterior table of frontal sinus

In our series only one patient presented with posterior table fracture with CSF leak. This patient was taken up for open reduction and CSF leak closure via Bicoronal approach. The lone patient who had fracture involving both anterior and posterior tables with frontal outflow tract block had a cannula placed in the frontal sinus under endoscopic guidance and left in place for 4 weeks.

Tips for frontal bone fracture repair:

1. All depressed fractures of more than one table width should be reduced
2. Titanium mini plates are very useful with good success rate
3. In comminuted fractures titanium mesh is ideal

Conclusion:

1. All frontal bone fractures need not be reduced
2. When there is posterior table fracture with CSF leak the patient should be treated as head injury patient
3. Depressed fractures with depression of more than the width of the frontal table alone need to be reduced
4. Frontal sinus outflow tract obstruction needs lot of expertise in management. It is always better to obliterate frontal sinus in these cases.

References:

1. IOANNIDES CH, FREIHOFER HP, FRIENS J. Fractures of the frontal sinus: a rationale of treatment. *Br J Plastic Surg* 1993; 46: 208-214.
2. LUCE EA. Frontal sinus fractures: guideline to management. *Plast Reconstr Surg* 1987; 80: 500-508.
3. Gonty, A.A., R.D. Marciani, and D.C. Adornato, (1999) Management of frontal sinus fractures: a review of 33 cases. *J Oral Maxillofac Surg* 57(4): p. 372–9; discussion 380–1.
4. Giant Frontal Mucocele Occurring 32 Years after Frontal Bone Fracture: A Case Report *Case Rep Neurol.* 2012 Jan-Apr; 4(1): 34–37. Published online 2012 January 25. doi: 10.1159/000336326 Yuuta Kamoshima,a,* Shunsuke Terasaka,a Yuji Nakamaru,b Dai Takagi,b Satoshi Fukuda,b and Kiyohiro Houkina
5. Goodale, R.L. and W.W. Montgomery, (1958) *Experiences with the osteoplastic anterior wall approach to the frontal sinus; case histories and recommendations.* *AMA Arch Otolaryngol* 68(3): p. 271–83.