



Endoscope assisted myringoplasty

Balasubramanian Thiagarajan ¹ Venkatesan Ulaganathan ²

¹ Stanley Medical College ² Meenakshi Medical College

Abstract:

Myringoplasty is commonly done under microscopy. This article discusses the experience of the authors in performing myringoplasty using endoscope. Endoscope is being widely used to perform various surgeries. Endoscopes are very useful while operating in cavities. In this study authors report their results of 50 myringoplasties performed using endoscope. This article reveals that results of myringoplasty performed using endoscope are more or less similar to that of myringoplasty performed using microscope ⁵.

Introduction:

Myringoplasty is a surgical procedure performed to close tympanic membrane perforations. The advent of operating microscope results of myringoplasty started showing dramatic improvements ¹. This is attributed to the accuracy of surgical technique. Major disadvantage of operating microscope is that it provides a magnified image along a straight line ². Success of myringoplasty should be assessed both subjectively and objectively.

Subjective indicators include:

1. Improvement in hearing acuity
2. Absence of ear discharge
3. Absence of tinnitus

Objective indicators are:

1. Healed perforation as seen in otoendoscopy
2. Improvement in hearing threshold demonstrated by performing puretone audiometry

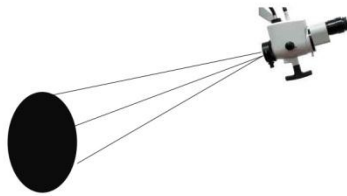


Figure showing microscopic line of magnification

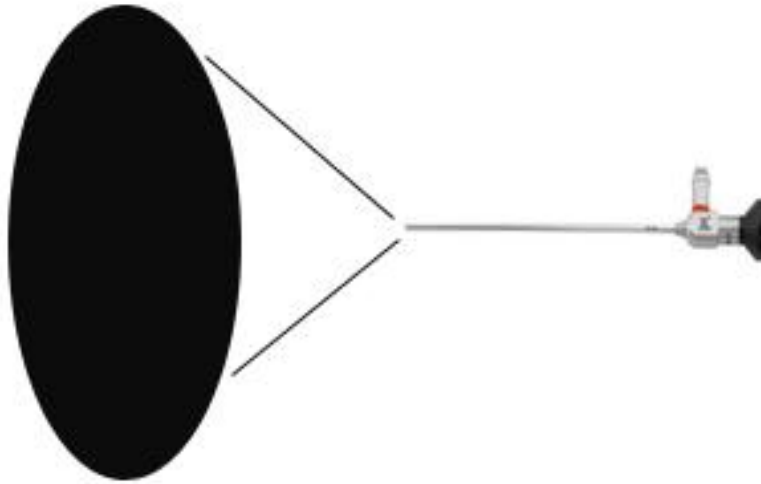


Figure showing the magnified line of vision in an endoscope

Advantages of endoscope³:

1. It provides an excellent magnified image with a good resolution
2. With minimal effort it can be used to visualize the nook and corners of middle ear cavity
3. Magnification can be achieved by just getting the endoscope closer to the surgical field
4. Antero inferior recess of external auditory canal can be visualized using an endoscope
5. Middle ear cavity can be visualized easily using an endoscope. Even difficult areas to visualize under microscopy like sinus tympani can easily be examined using an endoscope⁴.

Methodology:

Inclusion criteria:

1. Patients in the age group of 20 -40 were included in the study
2. All these patients had dry central perforation of ear drum
3. Patients with demonstrable degree of conductive deafness was chosen (at least 30 dB pure tone average)
4. Results of this procedure was compared to that of published results of microscopic myringoplasty

Puretone audiometry was performed for all these patients. All of them had 30 – 40 dB conductive hearing loss.

Success rate of endoscopic procedure was compared with that of various studies performed using microscopic approach. Internet survey revealed a success rate of 71% - 80% success rates in patients undergoing microscopic myringoplasty ⁶. This highly variable success rate was attributed to the different locations of perforations. Posterior perforations carried the best success rates i.e. 90% ⁷.

Procedure ⁸:

All these patients underwent surgery under local anesthesia.

Temporalis fascia graft is harvested under local anesthesia conventionally and allowed to dry. The external auditory canal is then anesthetised using 2 % xylocaine mixed with 1 in 10,000 adrenaline injection. About 1/2 cc is infiltrated at 3 - o clock, 6 - o clock, 9 - o clock, and 12 - o clock positions about 3mm from the annulus. The patient is premedicated with intramuscular injections of 1 ampule fortwin and 1 ampule phenergan.

Step I: Freshening the margins of perforation - In this step the margins of the perforation is freshened using a sickle knife or an angled pick. This step is very important because it breaks the adhesions formed between the squamous margin of the ear drum (outer layer) with that of the middle ear mucosa. These adhesions if left undisturbed will hinder the take up of the neo tympanic graft. This procedure will in fact widen the already present perforation. There is nothing to be alarmed about it.

Step II: This step is otherwise known as elevation of tympano meatal flap. Using a drum knife a curvilinear incision is made about 3 mm lateral to the annulus. This incision ideally extends between the 12 - o clock, 3 - o clock, and 6 - o clock positions in the left ear, and 12

- o clock, 9 - o clock and 6 - o clock positions in the right ear. The skin is slowly elevated away from the bone of the external canal. Pressure should be applied to the bone while elevation.

This serves two purposes:

1. It prevents excessive bleeding
2. It prevents tearing of the flap.

This step ends when the skin flap is raised up to the level of the annulus.

Step III: Elevation of the annulus and incising the middle ear mucosa. In this step the annulus is gradually lifted from its rim. As soon as the annulus is elevated a sickle knife is used to incise the middle ear mucosal attachment with the tympano meatal flap. This is a very important step because the inner layer of the remnant ear drum is continuous with the middle ear mucosa. As soon as the middle ear mucosa is raised, the flap is pushed anteriorly till the handle of the malleus becomes visible.

Step IV: Freeing the tympano meatal flap from the handle of malleus. In this step the tympano meatal flap is freed from the handle of malleus by sharp dissection of the middle ear mucosa. Sometimes the handle of the malleus may be turned inwards hitching against the promontory. In this scenario, an attempt is made to lateralise the handle of the malleus. If it is not possible to lateralise the handle of the malleus, the small deviated tip portion of the handle can be clipped. The handle of the malleus is freshened and stripped of its mucosal covering.

Step V: Placement of graft (underlay technique). Now a properly dried temporalis fascia graft of appropriate size is introduced through the ear canal. The graft is gently pushed under the tympano meatal flap which has been elevated. The graft is insinuated under the handle of malleus. The tympano meatal flap is repositioned in such a way that it covers the free edge of the graft which has been introduced. Bits of gelfoam are placed around the edges of the raised flap. One gel foam bit is placed over the sealed perforation. This gelfoam has a specific role to play. Due to the suction effect created it pulls the graft against the edges of the perforation thus preventing medialisation of the graft material.

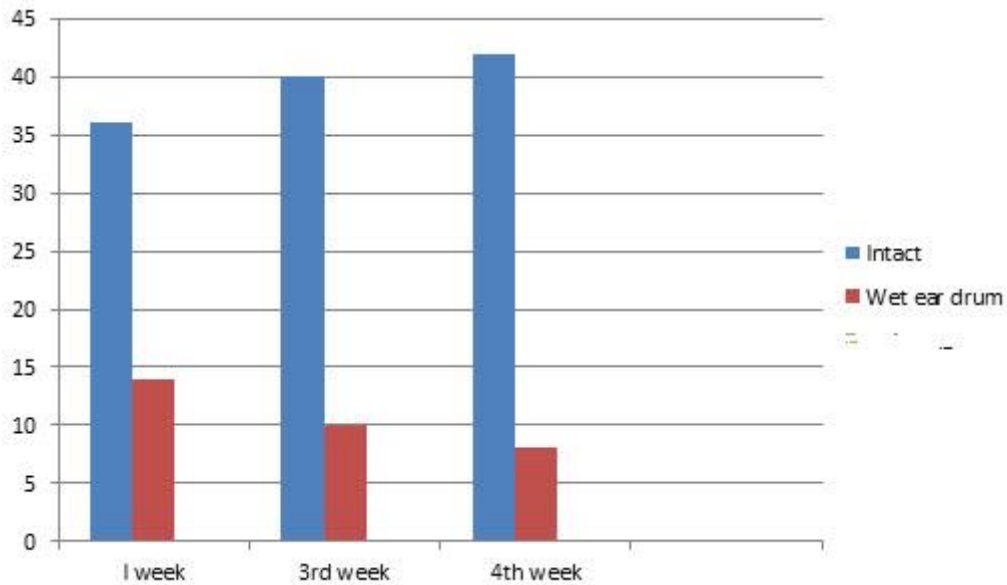
Results:

First week after surgery:

36 patients out of 50 had intact ear drum

4th week after surgery:

42 patients out of 50 had intact ear drum



Graph showing objective reports of a total of 50 patients who underwent endoscopic myringoplasty

Hearing improvement:

Pre op audiometry showed:

32 patients -30-35 dB hearing loss

18 patients – 35-40 dB hearing loss

Post op audiometry:

All these patients after endoscopic myringoplasty had a pure tone hearing average of 20 dB.

Advantages of endoscopic myringoplasty:

1. This surgical procedure fulfils the criteria of minimally invasive surgical procedure ⁹.
2. Equipment is portable
3. It is cost effective

Disadvantages:

1. Since the non-dominant hand is used to hold the endoscope only one hand is available of surgery
2. Learning curve is very steep

Conclusion:

Authors conclude that the results of endoscopic myringoplasty are comparable with that of microscope myringoplasty. Even though the learning curve is a little steep it is worthwhile exploring this option due to the obvious advantages.

References:

1. Dennis SP. Endoscopic assisted middle ear surgery. In: Glasscock ME III, Gulya AJ, eds. Surgery of the Ear. 5th ed. Hamilton: Elsevier, 2003: 325-34.
2. Endoscope assisted myringoplasty Jadav SP et al Singapore medical journal 2009;50 (5):510
3. Patil RN. Endoscopic tympanoplasty – Definitely advantageous (preliminary reports). Asian J Ear Nose Throat 2003; 25:9-13.
4. Khan I, Jan AM, Shahzad F. Middle-ear reconstruction: a review of 150 cases. J Laryngol Otol 2002; 116:435-9.
5. Vartiainen E, Nuutinen J. Success and pitfalls in myringoplasty: follow-up study of 404 cases. Am J Otol. 1993 May;14:301-5.
6. Pignataro L, Berta LGD, Capaccio P, Zaghis A. Myringoplasty in children: anatomical and functional results. J Laryngol Otol 2001;115:369-373.
7. Onal K, Uguz MZ, Kazikdas KC, Gursoy ST, Gokce H. A multivariate analysis of otological, surgical and patient related factors in determining success in myringoplasty. Clin Otolaryngol 2005;30:115-120.
8. <http://www.drtdbalu.com/myring.html>

9. Karhuketo TS, Ilomaki JH, Pukakka HJ. Tympanoscope-assisted myringoplasty. ORL J Otorhinolaryngol Relat Spec 2001; 63:353-7.