

Effectiveness of a formulated product (Gold Lotion) in improving the quality of life (QoL) of oncological cats: preliminary results.

Paolo Guazzi¹, Michiko Suzawa², Alessandro Di Cerbo^{3*}

¹Wiligelmo Veterinary Clinic, Modena, Italy

²Miyauchi Citrus Research Center, Takasaki, Gunma, Japan

³Department of Medical, Oral and Biotechnological Sciences, Dental School, University G. D'Annunzio of Chieti-Pescara, Chieti, Italy

Abstract

In the last years many scientific veterinary reports highlighted the pivotal role of nutrition also as a support in animals before surgical, chemotherapy and radiotherapy interventions. We aimed to evaluate the effectiveness of a dietary supplement named Gold Lotion (GL, 4 mL day for 6 months) as adjuvant of current pharmacological therapy in 18 cats affected by different tumors (digestive system lymphoma, carcinoma and cutaneous fibrosarcoma). Metabolic profile and oxidative stress parameters of cats resulted significantly improved after 6 months of GL supplementation (* $p < 0.05$, ** $p < 0.01$). The combined use of GL and pharmacological therapy not only significantly ameliorated digestive and hepatic functionality of all cats and reduced the overall overload of free radicals but also improved their quality of life (QoL). Unfortunately the life span expectancy did not improve and all cats died few weeks later after GL supplementation interruption due to metastases spread and a consequent clinical condition severe worsening.

Keywords: Nutrition, Radiotherapy, Carcinoma, Cat.

Accepted On May 30, 2017

Introduction

In the last years many scientific veterinary reports highlighted the pivotal role of nutrition to preserve physiological homeostasis [1], prevent secondary metabolic diseases [2] and neoplastic cachexy [3] as well as support animals before surgical, chemotherapy and radiotherapy interventions [4]. Another important element of the nutrition is represented by dietary supplements [5]. Despite the increasing use dietary supplements in pets only few scientific evidence of their efficacy have been described so far [5,6]. Among the emerging dietary supplements used in the oncological veterinary practice there are flavonoids [7], which are polyphenolic compounds mainly present in citrus fruits [8].

In vivo and *in vitro* literature reports highlighted the antitumor effects of a commercially available flavonoids-enriched supplement derived from citrus peel extract named Gold Lotion [9-11].

Gold Lotion (GL) is made of extracts derived from the peels of six citrus fruits (navel oranges, citrus hassaku, citrus limon, citrus natsudaikai, citrus miyauchi and satsuma) and known to be rich in flavonoids (0.45 mg/mL) and polymethoxyflavones (0.1 mg/mL). Molecular mechanisms, which are related to

flavonoids and polymethoxyflavones cancer prevention effect, range from carcinogen inactivation, antiproliferation, cell cycle arrest, apoptosis induction, angiogenesis inhibition, antioxidation and of multidrug resistance reversal [8,12].

We firstly propose the use of GL as adjuvant of current pharmacological therapy (e.g. corticosteroids) [13] in 18 cats affected by different tumors (digestive system lymphoma, carcinoma and cutaneous fibrosarcoma). Moreover, we evaluated the overall oxidative stress of cats, which is generally observed in oncological patients, to ascertain also the possible antioxidant effect of the GL.

Materials and Methods

Eighteen client-owned European neutered cats (8 females and 10 males) aged 11.7 ± 0.5 (mean \pm Standard Error of Mean) and affected by stage IV digestive system lymphoma (n=8, small intestine adenocarcinoma (n=4) and cutaneous fibrosarcoma (n=6) were evaluated over a 6 months period (Figure 1). All cats presented at least one or more of the following clinical symptoms: diarrhea, pultaceous feces, vomit, anorexia and dehydration.

Citation: Guazzi P, Suzawa M, Di Cerbo A. Effectiveness of a formulated product (Gold Lotion) in improving the quality of life (QoL) of oncological cats: preliminary results.. *J Vet Med Allied Sci* 2017;1(1):1-4.

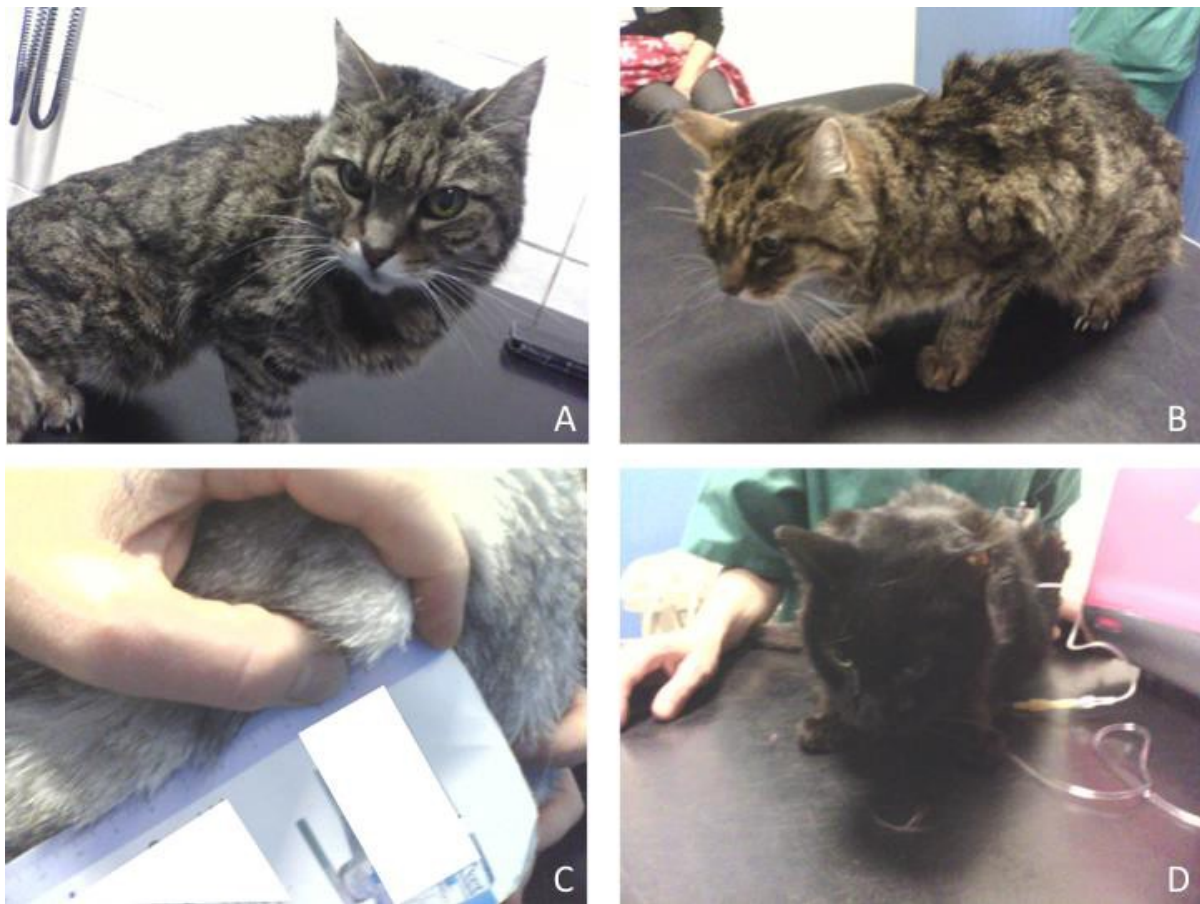

Figure 1. Cats enrolled in the evaluation. (A, D) European cat with stage IV digestive system lymphoma; (B) European cat with small intestine adenocarcinoma; (C) European cat with cutaneous fibrosarcoma.

Cytological (fine needle biopsy), histological (incisional biopsy) and hematobiochemical were performed at the beginning and, for some of them, at the end of the evaluation. Cats were randomly and equally assigned to receive L-asparaginase (400 U/kg/once), vincristine (0.025 mg/Kg/e.o.w.), cyclophosphamide (10 mg/Kg/e.o.w.), doxorubicin (1 mg/Kg/IV every 3 weeks) and/or prednisolone (2 mg/kg/day) or the same pharmacological treatment with Gold Lotion (4 mL/day) along with a standard commercial diet.

Blood samples were collected from each cat before and at the end of the evaluation period, after 6 months. Reactive oxygen metabolites (dROMs) and biological antioxidant potential (BAP), as indicators of disease-related oxidative stress, were measured by portable spectrophotometer on plasma samples according to procedure reported by Sechi [14]. Animal care was performed according to the national and international regulations (Italian regulation D.L.vo 116/1992 and European Union regulation 86/609/EC).

Statistical analysis

Data were analyzed using GraphPad Prism 6 software (GraphPad Software, Inc., La Jolla, CA, USA). All data are presented as the means \pm standard error of the mean and were first checked for normality using the D'Agostino-Pearson normality test. Differences in metabolic profile and oxidative stress parameters were analyzed using a two-way analysis of

variance (ANOVA) test followed by Bonferroni's multiple comparisons test. $p < 0.05$ was considered significant.

Results

After 3 weeks of treatment an overall significant decrease of the use of prednisolone and was observed for all cats. Interestingly, no signs of neoplastic lesions and clinical conditions worsening were observed in all cats. As shown in Figure 2, hematobiochemical analyses resulted significantly improved in the cats that received the pharmacological treatment along with Gold Lotion.

Glutamic-oxalacetic and glutamate pyruvate transaminase and alkaline phosphatase, significantly decrease from 35.70 ± 2.14 U/L to 17.50 ± 1.38 U/L, from 69.40 ± 2.90 U/L to 36.70 ± 1.18 U/L and from 121.6 ± 4.87 U/L to 50.80 ± 3.41 U/L, respectively in the pharmacological treatment+Gold Lotion group ($*p < 0.05$).

Also amylase, creatinine, glucose and phosphorous showed the same trend decreasing from 977.8 ± 45.40 U/L to 502.7 ± 39.66 U/L, from 2.13 ± 0.16 mg/dL to 1.33 ± 0.12 mg/dL, from 113.3 ± 2.94 mg/dL to 89.60 ± 2.07 mg/dL and from 7.53 ± 0.39 to 4.96 ± 0.29 mg/dL, respectively in the pharmacological treatment+Gold Lotion group ($*p < 0.05$). As to gamma-glutamyltransferase and albumin, they significantly decrease from 10.30 ± 0.36 U/L to 4.40 ± 0.33 U/L and from

3.50 ± 0.16 g/dL to 3.20 ± 0.24 g/dL, respectively in the pharmacological treatment+Gold Lotion group (**p<0.01).

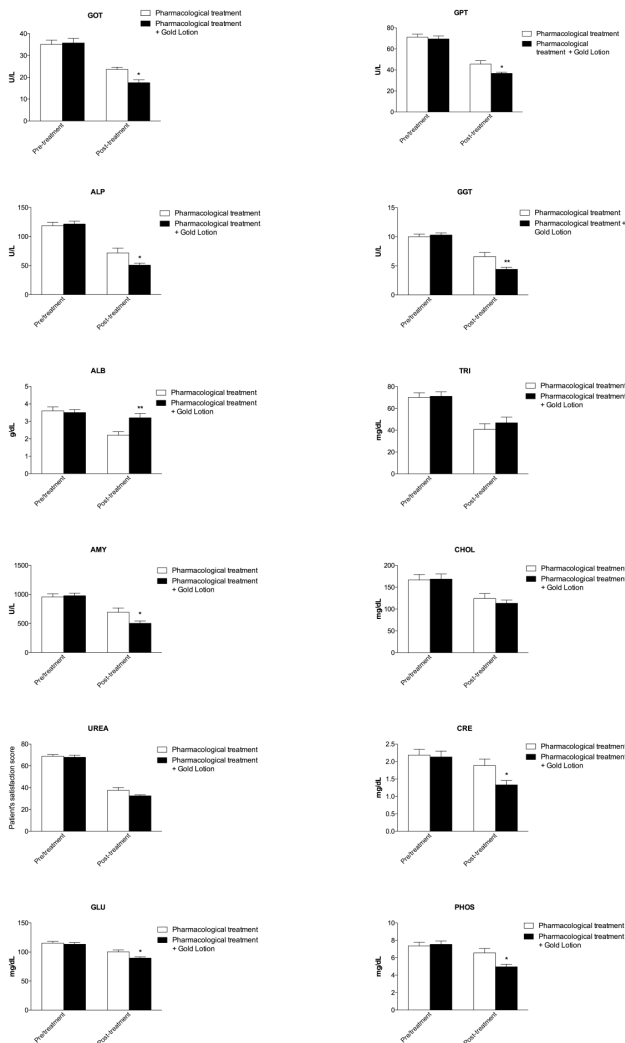


Figure 2. Graphical representation of metabolic profile of cats before and after 6 months of therapy administration. Glutamic-oxalacetic transaminase (GOT), glutamate pyruvate transaminase (GPT), alkaline phosphatase (ALP), gamma-glutamyltransferase (GGT), albumin (ALB), triglycerides (TRI), amylase (AMY), cholesterol (CHOL), urea, creatinine (CRE), Glucose (GLU), phosphorous (PHOS); *p<0.05, **p<0.01.

We also evaluate the oxidative stress parameters trend to evaluate the antioxidant activity of flavonoids and polymethoxyflavones present within Gold Lotion (Figure 3).

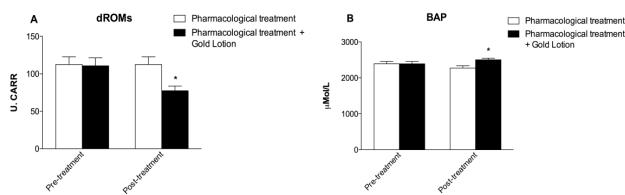


Figure 3. Graphical representation of oxidative stress parameters of cats before and after 6 months of therapy administration. (A) Reactive oxygen metabolites (dROMs) and (B) biological antioxidant potential (BAP), *p<0.05.

dROMs significantly decreased in the pharmacological treatment+Gold Lotion group from 110.7 ± 10.64 U. CARR to 77.41 ± 6.30 U. CARR (*p<0.05), while a slight but not significant increase was observed in the pharmacological treatment group. As to BAP, a significant increase in the pharmacological treatment+Gold Lotion group from 2391 ± 65.90 µMol/L to 2504 ± 44.89 µMol/L, while a slight but not significant decrease was observed in the pharmacological treatment group.

Conclusion

The combined use of GL and pharmacological therapy allowed all cats to ameliorate their digestive and hepatic functionality but also to reduce the overall overload of free radicals, which typically characterizes cancer [15]. Moreover, the GL supplementation avoided the rapid nutritional decay that frequently undermines oncological patients [16,17] thus improving the QoL of cats, nevertheless all cats died few weeks later after GL supplementation interruption due to metastases spread and a consequent clinical condition severe worsening. It is worth noting that GL taste was not always accepted by some of the cats, which therefore received it by means of a syringe without the needle.

Last but not least the significant reduction of dROMs and the significant improvement of BAP values (P<0.05) observed in cats, which received the GL clearly demonstrated the ability of the dietary supplement to reduce oxidative stress that typically characterizes oncologic patients and indicated a prompt response of their organism to counteract such condition. We can conclude that GL can be considered a valuable adjuvant in current pharmacological therapy of some feline tumors with poor prognosis to improve the QoL of the time before dying.

References

1. Phillips CJC. Nutrition and the Welfare of Farm Animals. Springer International Publishing.
2. Fascetti AJ. Nutritional management and disease prevention in healthy dogs and cats. Revista Brasileira de Zootecnia 2010;39(2):42-51.
3. Ogilvie GK. Interventional nutrition for the cancer patient. Clin Tech Small Anim Pract 1998;13(4):224-31.
4. Biller B. AAHA Oncology Guidelines for Dogs and Cats. J Am Anim Hosp Assoc 2016;52(4):181-204.
5. Freeman LM. Disease prevalence among dogs and cats in the United States and Australia and proportions of dogs and cats that receive therapeutic diets or dietary supplements. J Am Vet Med Assoc 2006;229(4):531-4.
6. Roudebush P, Schoenherr WD, Delaney SJ. An evidence-based review of the use of nutraceuticals and dietary supplementation for the management of obese and overweight pets. J Am Vet Med Assoc 2008;232(11):1646-55.
7. Athira KV, Madhana RM, Lahkar M. Flavonoids, the emerging dietary supplement against cisplatin-induced nephrotoxicity. Chem Biol Interact 2016;248:18-20.

Citation: Guazzi P, Suzawa M, Di Cerbo A. Effectiveness of a formulated product (Gold Lotion) in improving the quality of life (QoL) of oncological cats: preliminary results.. *J Vet Med Allied Sci* 2017;1(1):1-4.

8. Wang L. Anticancer activities of citrus peel polymethoxyflavones related to angiogenesis and others. *Biomed Res Int* 2014;453972.
9. Wu X. Inhibitory Effects of 4'-Demethylnobiletin, a Metabolite of Nobiletin, on 12-O-Tetradecanoylphorbol-13-acetate (TPA)-Induced Inflammation in Mouse Ears. *J Agric Food Chem* 2015; 63(51):10921-7.
10. Lai CS. Potent anti-cancer effects of citrus peel flavonoids in human prostate xenograft tumors. *Food Funct* 2013;4(6): 944-9.
11. Pan MH. Inhibition of citrus flavonoids on 12-O-tetradecanoylphorbol 13-acetate-induced skin inflammation and tumorigenesis in mice. *Food Science and Human Wellness* 2012;1(1): 65-73.
12. Chahar MK. Flavonoids: A versatile source of anticancer drugs. *Pharmacogn Rev* 2011;5(9):1-12.
13. McNeill CJ. Evaluation of adjuvant doxorubicin-based chemotherapy for the treatment of feline mammary carcinoma. *J Vet Intern Med* 2009;23(1):123-9.
14. Sechi S. An Antioxidant Dietary Supplement Improves Brain-Derived Neurotrophic Factor Levels in Serum of Aged Dogs: Preliminary Results. *J Vet Med* 2015;412501.
15. Dreher D and Junod AF. Role of oxygen free radicals in cancer development. *Eur J Cancer* 1996;32A(1):30-8.
16. Alshadwi A. Nutritional considerations for head and neck cancer patients: a review of the literature. *J Oral Maxillofac Surg* 2013;71(11):1853-60.
17. Muscaritoli M. The "parallel pathway": a novel nutritional and metabolic approach to cancer patients. *Intern Emerg Med* 2011;6(2):105-12.

Correspondence to:

Alessandro Di Cerbo

Department of Medical, Oral and Biotechnological Sciences,
Dental School

University G. D'Annunzio of Chieti-Pescara

Italy

Tel: +39 0871 3551

E-mail: alessandro811@hotmail.it