

Effect of internal pipe-based small intestinal plication on incision infection, intra-abdominal abscess, and incidence of intestinal fistula of patients with adhesive intestinal obstruction.

Ya-Ru Wang, Yong-Le Chen, Xiao-Liang Tang*

Colorectal Surgery Department, Baoji Central Hospital, Baoji, Shaanxi, PR China

Abstract

Objective: The aim of this paper is to study the effects of internal pipe-based small intestinal plication on incision infection, intra-abdominal abscess, and incidence of intestinal fistula of patients with Adhesive Intestinal Obstruction (AIO).

Methods: A total of 52 patients with AIO were divided into the control group (n=26) and study group (n=26) according to time of admission to hospital. The control group was given conventional surgical therapy, whereas the study group was given internal-pipe-based small intestinal plication. Recovery time for passage of gas by anus, length of stay, and incidence of complications of two groups were compared.

Results: The study group had significantly shorter recovery time for passage of gas by anus (29.3 ± 3.6 h) and LOS (6.1 ± 1.6 d) than the control group ($P < 0.05$). Before the treatment, two groups had no statistically significant difference in serum albumin ($P > 0.05$). After the treatment, the serum albumin of the study group was (34.8 ± 4.0) g/L, and the serum albumin of the control group was (28.5 ± 3.1) g/L, thereby showing statistically significant differences ($P < 0.05$). The incidence of complications (incision infection, intra-abdominal abscess, and incidence of intestinal fistula) of the study group is 3.85%, which is significantly lower than that of the control group (19.23%) ($P < 0.05$).

Conclusions: Internal pipe-based small intestinal plication showed a definite curative effect with few complications in AIO patients. It can be used in clinical practice.

Keywords: Adhesive intestinal obstruction, Complications, Internal pipe-based small intestinal plication.

Accepted on March 2, 2017

Introduction

Adhesive Intestinal Obstruction (AIO) is a common type of intestinal obstruction that often occurs after abdominal operation. Some patients with AIO can relieve their symptoms after conservative therapy. However, further surgical therapy is needed by patients with invalid conservative therapy or those who suffer from relapse after surgical therapy [1]. The internal pipe-based small intestinal plication treatment for AIO has achieved satisfying curative effect since its application in our hospital. Results are presented as follows.

Information and Methods

General information

A total of 52 patients with AIO in our hospital from February, 2015 to February, 2016 were enrolled in the study. They were diagnosed by clinical symptoms and imageological examination at the admission to hospital (Figure 1). Selection standards were as follows: diagnosed with extensive adhesion in operation, recurrent intestinal obstruction, and invalid conservative therapy. All patients signed the informed consent form. They were divided into the control group (n=26) and

study group (n=26) according to time of admission to the hospital. The study group has 16 males and 10 females aged 31-80 years old (average, 46.3 ± 5.3 years old). Causes of intestinal obstruction: 11 cases were caused by perforation of the digestive tract, 8 cases were caused by subtotal gastrectomy, 3 cases were caused by volvulus operation, and the other 4 cases were caused by others. The control group has 15 males and 11 females, aged 30-78 years old (average, 45.7 ± 5.5 years old). Causes of intestinal obstruction were as follows: 11 cases were caused by perforation of the digestive tract, 7 cases were caused by subtotal gastrectomy, 4 cases were caused by volvulus operation, and the rest (3 cases) were caused by others. The two groups did not show significant difference in terms of general information ($P > 0.05$), thereby indicating that they are comparable.

Methods

The control group was given conventional enterolysis. Patients with severe intestinal adhesion and could not be separated by conventional enterolysis were treated with one-stage anastomosis of affected intestine.

The study group was treated with internal pipe-based small intestinal plication. After epidural anesthesia, a cut was made at the right musculus rectus abdominis under the supine position to examine the intestinal adhesion conditions. Next, a cut was made on the peritoneum, and normal saline was injected, followed by blunt dissection. Anastomosis of adhesion intestine is implemented during surgery upon failure of separation. Gastrointestinal decompression is executed to patients with obvious intestinal pneumatosis or hydrops [2]. Intestinal canals were folded from the ileocecal valve. Interrupted suture of seromuscular layer was applied at about 8 cm away from the mesentery edge, thereby avoiding the corner of the intestinal canal. Double pouches were used at 15 cm of the ileocecal valve. The ileocecal valve was cut, and the silica gel stomach tube was placed inside. Small intestines were arranged according to their anatomical position. The drainage tube was placed inside conventionally before the operation was concluded. Conventional gastrointestinal decompression and enteral nutrition treatment are administered to both groups. The internal pipe is removed 10 d after the operation.

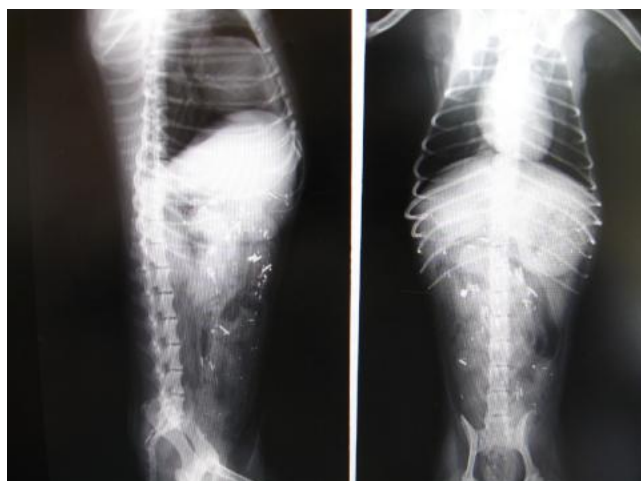


Figure 1. X-ray radiography of AIO.

Observation indexes [3]

Recovery time for passage of gas by anus, Length of Stay (LOS), and incidence of complications of two groups were analysed statistically. Complications include incision infection, intra-abdominal abscess, and intestinal fistula.

Statistical processing

This group of data was processed by SPSS19.0. Incidence of complications was expressed by percentage and tested by χ^2 .

Table 3. Comparison of incidence of complications between two groups (case %).

Group	Cases	Incision infection	Intra-abdominal abscess	Intestinal fistula	Total
Study group	26	1 (3.85)	0	0	1 (3.85)
Control group	26	2 (7.69)	1 (3.85)	2 (7.69)	5 (19.23)
χ^2	/	/	/	/	12.119

The LOS and recovery time for passage of gas by anus were expressed as mean \pm standard deviation ($\bar{x} \pm S$) and tested by t-test. $P < 0.05$ represents statistically significant difference.

Results

Operation indexes

The study group has significantly shorter recovery time for passage of gas by anus (29.3 ± 3.6) h and LOS (6.1 ± 1.6) d than the control group ($P < 0.05$) (Table 1).

Table 1. Comparison of operation indexes between two groups ($\bar{x} \pm S$).

Group	Cases	Recovery time for passage of gas by anus (h)	LOS (d)
Study group	26	29.3 ± 3.6	6.1 ± 1.6
Control group	26	40.1 ± 3.5	11.2 ± 2.3
t	/	11.781	9.282
P	/	0.000	0.000

Serum albumin levels before and after treatment of two groups

Before the treatment, the two groups had no statistically significant difference in serum albumin ($P > 0.05$). After the treatment, the serum albumin of the study group is (34.8 ± 4.0) g/L, whereas the serum albumin of the control group is (28.5 ± 3.1) g/L, thereby showing a statistically significant difference ($P < 0.05$) (Table 2).

Table 2. Serum albumin levels before and after treatment of two groups (g/L).

Group	Cases	Before	After
Study group	26	26.2 ± 3.2	34.8 ± 4.0
Control group	26	25.7 ± 3.1	28.5 ± 3.1
t	/	1.232	5.182
P	/	> 0.05	< 0.05

Complications

The incidence of complications of the study group was 3.85%, which was significantly lower than that of the control group (19.23%) (Table 3).

Discussions

AIO is a common abdominal operation complication. AIO incidence increased recently with the increasing number of abdominal operations like trauma and tumor operations. Intestinal obstruction is mainly represented as simple intestinal obstruction, and will hardly convert into strangulated intestinal obstruction. Moreover, the strangulated intestinal obstruction is the principal manifestation [4]. Most intestinal obstructions are acquired, but few are caused by congenital factors in enterocoelia, such as congenital aplasia or meconium peritonitis. Common causes are enterocoelia inflammation, damages, hemorrhage, and enterocoelia foreign matter, including talcum powder or gauze left in enterocoelia after abdominal operations and peritonitis. Abdominal radiotherapy and abdominal chemotherapy can cause AIO [5]. Most intestinal adhesions do not have clinical symptoms, because adhesion may not form obstruction. Some adhesions are accompanied with gentle paroxysmal stomach ache. AIO only occurs when intestinal adhesion influences the passage of peristalsis, when adhesion intestines are folded into sharp corners and torsion, or adhesion intestines compress intestines or form internal hernia [6]. Acute intestinal obstruction is common in the gastroenterology department; this can be induced by abdominal infection, surgical history, and intestinal parasite. Viewed from the physiological perspective, AIO is an inflammatory reaction that occurs after injury, which prevents dispersion of inflammatory factors and local inflammation in intestines. AIO is a healing mechanism and is a natural defensive reaction [7]. According to clinical studies, intestinal adhesion will not cause intestinal obstruction if it does not influence normal passing of materials and does not need surgical treatment. If the patients have repeated abdominal pains, intestinal obstruction occurs, and surgical treatment is needed [8].

Existing AIO treatments mainly include surgical and non-surgical treatments. Non-surgical treatments mainly involve elimination of intestinal edema, reducing materials in intestines, gastrointestinal decompression, and improving nutritional status of patients; non-surgical treatments can only relieve intestinal obstruction of patients [9]. Conventional enterolysis can relieve clinical symptoms of patients, but it also has disadvantages of high recurrence and high incidence of complications. Internal pipe-based small intestinal plication can prevent formation of sharp corners by the intestinal loop to the maximum extent via elasticity of the built-in pipe and protect intestinal canal from adhesion, thereby reducing incidence of secondary AIO [10]. At the same time, intestinal canal arrangement is close to the anatomical position and avoids intestinal twist, which is conducive to normal passing of materials through the intestines, facilitating recovery of peristalsis, and accelerating recovery of passage of gas by anus. The study group had significantly shorter recovery time of passage of gas by anus and LOS compared with the control

group. With respect to complications, only one case (3.85%) in the study group had incision affection, which is significantly less than in the control group (19.23%). The internal pipe-based small intestinal plication for AIO can reduce the incidence of complications after surgical treatments.

Conclusion

Internal pipe-based small intestinal plication has a definite curative effect on AIO. It shortens recovery time of passage of gas by anus and LOS and reduces the incidence of complications after surgical treatment. It is a safe treatment. However, patients' adaptation to the operation needs to be considered.

References

1. Chen Y, Bian Y, Sun Y, Kang C, Yu S. Identification of 4-aminoquinoline core for the design of new cholinesterase inhibitors. *Peer J* 2016; 4: 2140.
2. Liu Y, Guan B. Drug-drug interaction between the infection diseases treatment drugs ketoconazole and bruceine B. *Lat Am J Pharm* 2015; 34: 1897-1899.
3. Guo XK, Sun HP, Shen S, Sun Y, Xie FL. Synthesis and evaluation of gambogic acid derivatives as antitumor agents. Part III. *Chem Biodivers* 2013; 10: 73-85.
4. Uliana MP, Silva AGD, Fronza M, Scherer R. In vitro antioxidant and antimicrobial activities of *costus spicatus* swartz used in folk medicine for urinary tract infection in Brazil. *Lat Am J Pharm* 2015; 34: 766-772.
5. Han R, Sun Y, Kang C, Sun H, Wei W. Amphiphilic dendritic nanomicelle-mediated co-delivery of 5-fluorouracil and doxorubicin for enhanced therapeutic efficacy. *J Drug Target* 2016; 12: 1-9.
6. Khamesipour F, Tajbakhsh E. Analyzed the genotypic and phenotypic antibiotic resistance patterns of *Klebsiella pneumoniae* isolated from clinical samples in Iran. *Biomed Res-India* 2016; 27: 1017-1026.
7. Hussain A, Ibrahim MIM, Malik M. Assessment of disease management of acute respiratory tract infection at community pharmacies through simulated visits in Pakistan. *Lat Am J Pharm* 2012; 31: 1435-1440.
8. Tehrani P, Shojaei S. RBC deformation analysing within capillary blood flow using FSI method. *Biomed Res-India* 2016; 27: 1000-1005.
9. Petrovich DA. Age differences of morbidity of a right and left sided breast cancer: influence of chronic pathology of internal genitals and reproductive organs surgery. *Biomed Res-India* 2016; 27: 1071-1074.
10. Christ-Crain M, Stolz D, Bingisser R, Müller C, Miedinger D, Huber PR, Zimmerli W, Harbarth S, Tamm M, Müller B. Procalcitonin guidance of antibiotic therapy in community-acquired pneumonia: a randomized trial. *Am J Respir Crit Care Med* 2006; 174: 84-93.

***Correspondence to**

Xiao-Liang Tang

Colorectal Surgery Department

Baoji Central Hospital

PR China