



DISK BATTERIES IN THE ESOPHAGUS OF NIGERIAN CHILDREN: CASE SERIES

LUCKY OBUKOWHO ONOTAI

UNIVERSITY OF PORT HARCOURT TEACHING HOSPITAL Nigeria

ABSTRACT

Foreign body (FB) ingestion is common in clinical practice especially in children. Its impaction in the esophagus constitutes an important cause of morbidity and mortality in our environment. Due to technological advancement and increase use of disk batteries to power children toys and remote control gadgets, ingestion of disk batteries is now commonplace. In our environment there is paucity of information on disk batteries hence we decided to present case series of disk batteries in the esophagus of children highlighting the peculiarities of disk batteries, the dangers posed by them, the mode of retrieval, complications encountered, and possible recommendations to curtail the increasing occurrence.

Introduction

Foreign body in the oesophagus is relatively common in children compared to adults. Its incidence is gradually increasing with the growing popularity of miniature electronic toys¹. It also poses a diagnostic challenge with respect to its diverse presentation, ranging from airway obstruction that can be life threatening to subtle respiratory symptoms that are often misdiagnosed². These foreign bodies of the aerodigestive tract are commoner in children under the age of 4 years¹ due to their indiscriminate habit of putting objects in the mouth, incomplete dentition, and immature swallowing coordination²⁻⁵.

Foreign bodies encountered in the oesophagus, occasionally find their way to the stomach⁶ and eventually expelled from the anus. However, some are trapped in the oesophagus. Esophageal foreign bodies are typically impacted at any of the following three normal anatomic esophageal narrowing: at the level of cricopharyngeus muscle, level of the aortic arch, and level of lower esophageal sphincter⁶. Among foreign bodies lodged in the oesophagus, the disc batteries portend more danger due to its destructive tendencies⁷⁻⁹. Disc batteries are alkaline batteries which are used to power commonly found electronic portable devices like wrist watches, toys, calculators, and hearing aids⁷. Alkali causes burns by liquefactive necrosis when in contact with mucous membrane^{6,7}.

Button batteries contain mercury, silver, zinc, manganese, cadmium, lithium, sulfur oxide, copper, brass, or steel as the components of the anode⁸⁻¹⁰. When mucosal surfaces are in contact with the anode (negative pole) there is usually associated damage to the mucosa^{6,7}. There are three battery systems commonly implicated in high risk of mucosal damage; those with manganese dioxide, silver oxide, and mercuric oxide^{7, 8, 9}. The alkaline electrolytes in these systems are usually 26% to 45% potassium hydroxide or sodium hydroxide which is strong enough to cause rapid liquefactive necrosis of tissue^{6,7}. In disk battery ingestion, the mechanism of injury occurs by three different means including direct corrosive action, low voltage burns, and pressure necrosis^{6, 8, 11}. Liquefactive necrosis and perforation can occur within a period of 4 to 6 hours after a disk battery is lodged in the esophagus⁸.

The risk of complications increases with a prolonged presence of the battery in oesophagus prior to removal, the orientation of the foreign body in the oesophagus, and surface in contact with the anode¹. The process of removal can also increase the risk of complications⁶.

There are various complications associated with disk battery ingestion, ranging from minor esophageal mucosal burns which can lead to subsequent oesophageal strictures to trachea-oesophageal fistula, and even aorto-oesophageal fistula^{1, 8}.

In our environment there is paucity of information on disk batteries hence we decided to present a case series of disk batteries in the esophagus of children that we managed highlighting the peculiarities of disk batteries, the dangers posed by them, the mode of retrieval, complications encountered, and possible recommendations to curtail the increasing occurrence.

Case I:

A 3 years old male child was referred to Kinx Medical Consultant Clinic in Port Harcourt Rivers State, Nigeria, from a Rural Area within Rivers State with 6 months history of poor feeding, chronic cough and progressive difficulty in breathing. No associated fever, rhinological and otological symptoms. No history of foreign body aspiration or ingestion. He was being managed for bronchial asthma and lobar pneumonia by a General Practitioner in a Private clinic in a village outside Port Harcourt before he was referred. He was the 3rd child in a family of 3 siblings; father is a civil servant while the mother is a petty trader.

General examination revealed a pre-school child chronically ill looking, drooling of saliva from the mouth and in mild respiratory distress. He was not pale, afebrile and anicteric.

Chest findings revealed mild sub-costal and inter-costals recessions, respiratory rate of 28 cycles per minute and transmitted breath sounds. On examination of the mouth and oral cavity there were no abnormal intraoral findings apart from the pooling of saliva in the mouth. There were no associated neck lymph nodes. The examinations of the other systems appeared normal.

An urgent chest and neck radiograph done confirmed and located the site of impaction of a roundish radio-opaque foreign body in the esophagus (figure 1 and 2). The results of haematological and biochemical investigations were all within normal limits. The patient was immediately worked up for rigid esophagoscopy and removal of foreign body under general anaesthesia with endotracheal intubation. At esophagoscopy the foreign body was found in the cricopharyngeal sphincter impacting on the larynx posteriorly. The foreign body was extracted with the aid of foreign body grasping forceps. Further examination of the foreign body revealed a disk battery covered with food substances with signs of corrosion (figure 3 and 4). The mucosa of the oesophagus appears eroded at the site of impaction. Nasogastric tube was immediately passed for tube feeding and purpose of stenting the oesophagus. However, this patient later developed a short segment oesophageal stricture which was subsequently managed conservatively with serial oesophageal dilatations and was discharged home satisfactorily after 3 months of hospital stay.

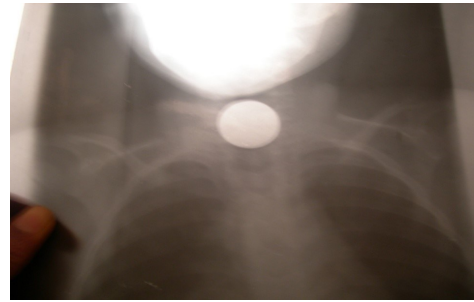


Fig 1 : Plain radiograph of neck including chest showing Roundish radiopaque object in the esophagus

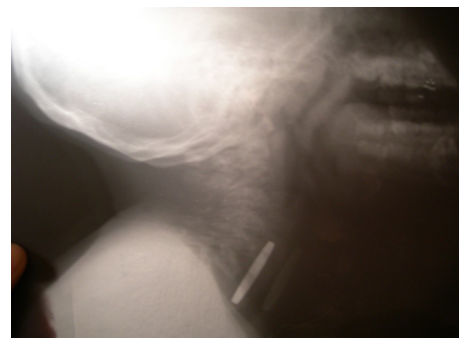


Fig 2: Plain radiograph of the lateral soft tissue neck showing radiopaque object in the esophagus.

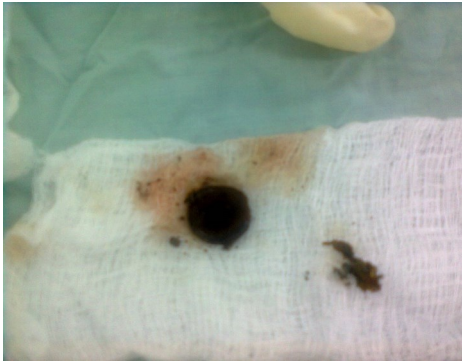


Fig 3 : Disk battery covered with food debris after
Extraction from the esophagus

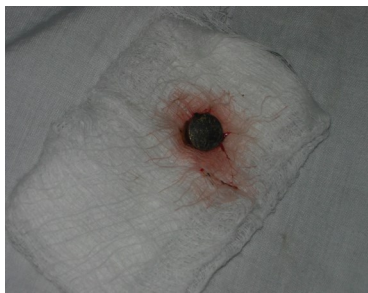

Fig 4: Disk battery after removal of food debris covering its surface

Case 2:

A 5 years-old female child was referred to Kinx Medical Consultant Clinic in Port Harcourt Rivers State, Nigeria, with 48 hours history of sudden inability to swallow food and water following ingestion of an object while playing with her toys. No associated fever, rhinological and otological symptoms. She first presented to a Paediatric Consultant clinic within the city where an urgent chest radiograph done revealed a roundish radiopaque material in the distal 3rd of the oesophagus (figure 5). Based on this finding she was referred to us for further expert management. She was the 1st child in a family of 2 siblings; father is a business man while the mother is a civil servant.

General examination revealed a child not ill looking, not in obvious respiratory distress conscious and alert. She was not pale, afebrile and anicteric. Chest findings were normal. On examination of the mouth and oral cavity there were no abnormal intraoral findings apart from the pooling of saliva in the mouth. There were no associated neck lymph nodes. The examinations of the other systems appeared normal.

The results of haematological and biochemical investigations were all within normal limits. The child was immediately worked up for rigid esophagoscopy and removal of foreign body under general anaesthesia with endotracheal intubation. At esophagoscopy the foreign body was found in the distal 3rd of the oesophagus and was extracted with the aid of foreign body grasping forceps without any complication.

Examination of the foreign body revealed a disk battery covered with recent food materials with no signs of corrosion (figure 6 and 7). The mucosa of the oesophagus appeared normal at the site of impaction but there was slight bleeding noticed after a forceful pulling on the foreign body during the extraction process. Nasogastric Tube was immediately passed after the bleeding was controlled. Post-operative check radiograph done revealed no features of oesophageal perforation; patient was subsequently managed conservatively and was discharged home to continue follow-up visits on out-patient basis.

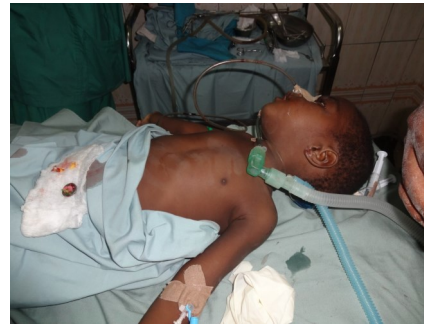

Fig 6: Child still lying on theatre table immediately after extraction of foreign body (Disk battery) after extraction from the esophagus

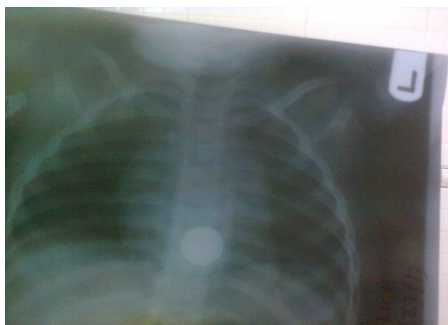


Fig 5: Plain chest radiograph showing roundish radiopaque object in the distal 3rd of esophagus

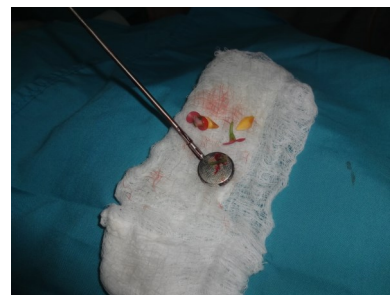

Fig 7: Disk battery after extraction

Case 3

A 2 years 6 months old male child was referred to Kinx Medical Consultant Clinic in Port Harcourt Rivers State, Nigeria, with 24 hours history of sudden refusal of feeds. No associated history of sudden cough and chocking. No fever, rhinological and otological symptoms. He first presented to a Paediatric Consultant clinic within the first 6 hours of incidence where an urgent chest radiograph done that revealed a roundish radiopaque material in the middle 3rd of the oesophagus (figure 8). Based on this finding he was referred to us immediately for further expert management. He was the only child of parents after 12 years of marriage; father is an engineer working with an oil company while the mother is a civil servant.

General examination revealed a child not ill looking, not in obvious respiratory distress conscious and alert. He was not pale, afebrile and anicteric. Chest findings were normal. On examination of the mouth and oral cavity there were no abnormal intraoral findings apart from the pooling of saliva in the mouth. There were no associated neck lymph nodes. The examinations of the other systems appeared normal.

The results of haematological and biochemical investigations were all within normal limits. The child was immediately worked up for rigid esophagoscopy and removal of foreign body under general anaesthesia with endotracheal intubation. At esophagoscopy the foreign body was found in the middle 3rd of the oesophagus and the disk battery slipped off from the grasping forceps into the stomach.

Immediate post operative plain radiograph of the chest and abdomen revealed the foreign body in the stomach (figure 9).

Meanwhile, the child was discharged home to continue conservative management. However, on the 4th day after discharge from the hospital, the parents called to inform us that the child passed out the foreign body (disk battery) through the anus.

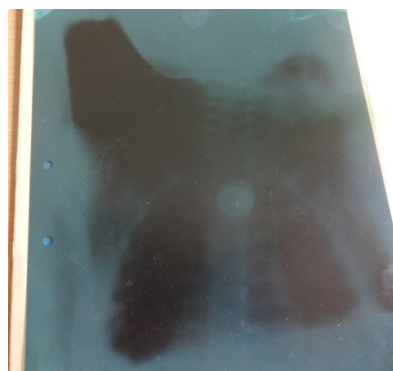


Fig 8: Plain chest radiograph showing roundish radiopaque object in the middle 3rd of esophagus

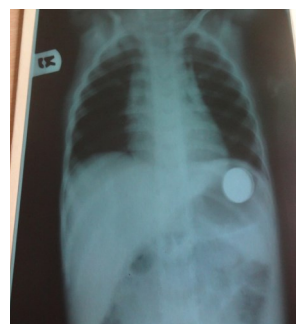


Fig 9: Plain chest and abdominal radiograph showing roundish radiopaque object in the stomach of the child.

Case 4:

A 4 years old male child was referred to Kinx Medical Consultant Clinic in Port Harcourt Rivers State, Nigeria, from a Private clinic in Port Harcourt with a history 1 day history of difficulty in swallowing food and slight cough. The father found a remote control device in his hands and equally noticed the absent of the disk battery that powered the device. No associated fever, rhinological and otological symptoms. He was the 2nd child in a family of 4 siblings; father is an Engineer while the mother is a university lecturer.

General examination revealed a pre-school child not ill looking and not in painful distress. On examination of the mouth and oral cavity there were no abnormal intraoral findings apart from slight pooling of saliva in the mouth. There were no associated neck lymph nodes. The examinations of the other systems appeared normal.

An urgent lateral chest and neck radiograph done confirmed and located the site of impaction of a roundish radio-opaque foreign body in the esophagus (figure 10). The results of haematological and biochemical investigations were all within normal limits. The patient was immediately worked up for rigid esophagoscopy and removal of foreign body under general anaesthesia with endotracheal intubation.

At esophagoscopy the foreign body was found in the cricopharyngeal sphincter. The foreign body was extracted with the aid of foreign body grasping forceps. Further examination of the foreign body revealed a disk battery (figure 11). The mucosa of the oesophagus appears normal. Postoperatively, he was managed with antibiotics and analgesics and was discharged home satisfactorily after 48 hours of hospital stay.

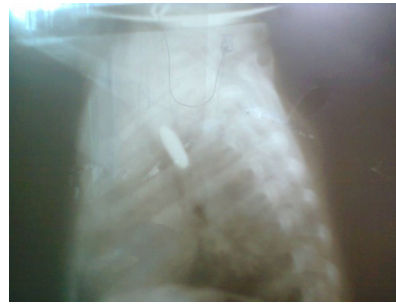

Fig 10: Plain lateral radiograph of the chest showing roundish radiopaque object in the esophagus of the child.

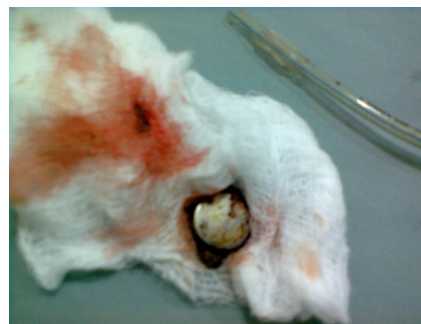

Fig 11: Disk battery after extraction from the oesophagus of the child

Discussion:

The incidence of disk battery ingestion in the paediatric age group is on the rise, and this has been attributed to the growing number of portable electronic gadgets using it as source of power. Various researchers have noted this in their studies in the past ^{1, 3-7}.

A coin impaction in the esophagus can mimic the appearance of a disk battery; however, it is associated with fewer complications when compared to disk batteries¹. In most cases disk battery impaction in the esophagus can only be differentiated from a coin after its extraction since both of them have similar radiological findings.

In our case series, ingestion of disk batteries commonly occurred in children within the age group 1-5 years old which agrees with the findings of previous researchers^{1, 3, 4}. Onotai and Etawo in 2012 in their study found age group 0-10 years to have the highest number (47.14%) of oesophagoscopy carried out for foreign body removal. The reason for the age range difference was because their study was not exclusive to disk batteries in the esophagus of children⁶.

Furthermore, we found that male children were more affected than females which agree with the findings of Okhakhu et al in 2013⁷. This is probably due to the more active nature of male children who tend to explore their environment more than their female counterparts making them to be more prone to foreign body impaction in their orifices^{4, 12}.

Up to 35% of oesophageal foreign bodies in children were asymptomatic^{6, 11}, so events witnessed by either patient's guardian or sibling creates room for early presentation and intervention just like in the case of the 4th patient in our series. The father of the patient was able to give us a reliable history of child playing with an electronic gadget that has a missing disk battery.

Unwitnessed cases with sudden symptoms of choking, gagging, drooling of saliva, coughing, wheezing, dysphagia, dyspnea, neck or chest pain, can also present early^{6, 11}, this depiction was obtained in cases 2 and 3 in our series. However unwitnessed cases especially the patients that are not symptomatic can be misdiagnosed, eventually leading to long duration of foreign body in oesophagus before eventual removal¹⁰ as seen in the first case in our series where the foreign body stayed up to 6 months before it was extracted. Unfortunately, there was a complication of esophageal stricture because of the long duration of impaction of the foreign body with the oesophageal mucosa.

The use of plain radiographs in locating the site and type of foreign bodies in the aerodigestive tract was found to be very helpful in our study and its importance cannot be over emphasized. Moreover, the findings of other researchers have attested to this^{1, 7, 10, 11}.

The procedure commonly employed in the retrieval of oesophageal foreign body is the rigid oesophagoscopy. This was employed in all the cases we encountered in our series. However, there was a failed extraction in the third case but the foreign body was displaced into the stomach and was subsequently passed out few days later through the anus.

Conclusion:

Disk batteries in the esophagus no doubt pose a source of danger to children in our setting. Early presentation and prompt diagnosis is important to prevent complications that can arise from the devastating effects of the corrosive agents in the battery. However, to further reduce the morbidity associated with this condition, parents and care givers should be more vigilant while their children are playing with toys that are powered with disk batteries. Above all, the government can prohibit the use of disk batteries in children toys and other household electronic gadgets.

References:

- 1 Okpala N.C. Disc batteries impaction in the oesophagus. *Journal of Science and Technology* 2008; Vol 28, No. 1 pp 1-3.
- 2 Anil K.L. *Current Diagnosis and Treatment in Otolaryngology- Head and Neck Surgery*. 3rd Ed. McGraw hill companies, 2011; New York. Pages 543-54.
- 3 Ibekwe M.U, Onotai L.O, Otaigbe B. Foreign bodies in the Ear, Nose and Throat in children: a five year review in Niger Delta. *Afr J Paediatr Surg*, 2012. 9 issue 1: 3-7.
- 4 Onotai L.O, Ebong M.E: Pattern of Foreign body impactions in the tracheobronchial tree in University of Port-Harcourt Teaching Hospital. *Port Harcourt Med J* 2011, vol 5(2): 130-135.
- 5 Onotai L.O, Ibekwe M.U, George I. Impacted Foreign Bodies in the Larynx of Nigerian Children. *J Med Med Scs* 2012, vol3 (4): 217-226.
- 6 Onotai L.O. and Etawo U.S. : The challenges of Rigid Oesophagoscopy in the Management of Oesophageal Foreign Bodies in Port Harcourt. *International journal of medicine and medical sciences*. Vol 2 (5) pages 108-113, may 2012.
- 7 Okhakhu A.L, Okolugbo N.E., Onyeagwara N.C: Disc Battery in the Nasal Cavity; Case Series. *International journal of modern and alternative medicine research*. Vol 5((8) pages 5-8.
- 8 Umana A, Offiong M, Kuni J, Akpan U, Adekanye A, Mgbe R, Etiuma A, Ewa A. Esophagopleural Fistula In A 3 Year Old Child Following Disk Battery Ingestion.. *The Internet Journal of Otorhinolaryngology*. 2010 Volume 13 Number 2.
- 9 Chan YL, Chang SS, Kao KL, Liao HC, Liaw SJ, Chiu TF, et al. Button battery ingestion: an analysis of 25 cases. *Chang Gung Med J*. Mar 2002; 25(3):169-74.
- 10 Umana A.N, Offiong M. E, Atana Uket Ewa, Francis P, Abiola Grace Adekanye, Mgbe R.B, Akpan N, Basseyy A. Foreign body (disk battery) in the oesophagus mimicking respiratory problem in a 13 months old baby-delayed diagnosis. *Journal of Medicine and Medical Science*. Mar 2011; 2(3) 714-717.
- 11 Umana A, Offiong M, Mgbe R, Etiuma A, Adekanye A, Ewa A, Ette V. Disk Battery Foreign Bodies In Children And Major Outcomes In The Southern Part Of South Nigeria. *The Internet Journal of Otorhinolaryngology*. 2012 Volume 14 Number 2.
- 12 Okoye BCC, Onotai LO: Foreign Bodies in the nose *Niger J Med* 2006; 15(3):301-4.