

Diagnosis study on sports injuries combined with medical imaging technology.

Bin Lv, Sihua Li*

Capital University of Physical Education and Sports, Beijing, PR China

Abstract

Using medical imaging technology to diagnose the athletes' sports injuries can help to accurately judge the specific damage of the body tissues or organs, and it is very important for the follow-up clinical treatment and the understanding of physical condition of the athletes. At present, the commonly used medical imaging technology has ultrasound diagnosis, X-ray radiography, MRI imaging and CT imaging technology. Through the research on the principle and characteristics of the four kinds of imaging techniques, they are not the same in the diagnosis and application of sports injuries. In order to research the specific applications of medical imaging technology in sports this work used 77 basketball players in one province of China as the research object. Based on the specific injury situation of athletes, X-ray or other imaging technology was used for sports injury imaging. Respectively, the 2015 sports trauma and previous trauma in 2015 were compared to the statistics, to understand the overall physical condition of the basketball players, and provide the diagnostic basis for the follow-up treatment of basketball players.

Keywords: Sports injuries, Medical imaging, Basketball players.

Accepted on January 15, 2017

Introduction

Sports injuries are a problem that almost every athlete will face, and even bring a lifetime of pain. Many excellent athletes have left their careers because of sports injuries. With the continuous pursuit of competitive sports and breakthrough, the players continue to increase their intensity, difficulty, and in the process of constantly beyond, it also bring more sports injuries to athletes [1]. Although people have paid more and more attention to sports injury, and studied the various measures to reduce the injury, according to the statistical research in recent years it can be seen that the phenomenon of athletes injury in sports activities is more widespread, and almost all of the retired athletes will have a trauma [2]. In order to avoid sports injuries to athletes to bring more influence, it should carry on the accurate and timely diagnosis to the sports wound after being injured. According to the diagnosis results, select the corresponding treatment means, so as to speed up the recovery of athletes, and reduce the pain of sports injuries to athletes.

For the diagnosis of sports injuries, the medical imaging technology is generally used to complete the clinical diagnosis and the medical image data provides the basis for clinical diagnosis. The commonly used medical imaging technology has ultrasound, X-ray image technology, CT technology, and MRI technology. They have their own advantages and disadvantages, and according to the different situation, select a more appropriate medical imaging technology [3]. In order to further analyze the application value of medical imaging technology in sports trauma diagnosis, through injury

investigation and analysis to our country basketball players of a province in 2015, the medical image technology is fully used to analyze athletes' injuries, understand the injury situation of athletes, which has a certain reference for the follow-up prevention and control and the quantity arrangement of movement in basketball.

Sports Injuries

Current situation of sports injuries

Sports trauma is the process in which tissues or organs are damaged when playing a game [4]. The occurrence of sports injuries is not caused by a single factor but is related to sports training, physical education, sports competitions, sports events and corresponding technical movements, which has great influence on the sports participants, is serious threat to their health and even sports. Because the modern competitive sports develop in the direction of higher, faster and stronger, in order to pursue a better score and break the limit of the sports project, sports athletes have been increasing training intensity and load [5]. In 2016 Rio Olympic Games, a total of 27 world records were broken of which 5 were broken by China. All over the world is in the pursuit of a breakthrough in sports. However, the training of athletes with high strength and high load is also bringing more and more serious injuries, and the proportion of sports injuries is gradually increasing. This type of injury is not only confined to long-term sports athletes, even new athletes who just accept physical training may also be damaged because of poor physical quality and technical

training is not enough [6]. In addition to that in the present competitive sports, highly difficult technical action makes the athletes will inevitably have an accident and cause injury in the training process, such as gymnastics, diving, etc. Once the sports injuries occur, it will cause damage to the athletes' training system. Higher training intensity will affect the performance of sports, and seriously affect the physical health of athletes. At the same time, it will bring great psychological pain. Therefore, many athletes terminate their athletic career, resulting in a great waste of manpower and material resources [7]. Figure 1 shows the images of trauma occurring due to accidents.



Figure 1. Sports injuries in sports.

The trauma caused by the movement of athletes will be different because of the different characteristics of the sport. For the majority of athletes who are in the same sport, the sport trauma and occupational disease caused by long term sport is different [8]. Take a case study of the people's favorite and well known Olympic events in China for example: In the shooting movement, because the firing position must maintain the absolute static, both their waist and the cervical vertebra have a certain degree of damage, and the distortion of the cervical spine will be accompanied by the dislocation of the joint, which brings great pain to the shooter; The table tennis players can be affected by cartilage injury and ligament during the process of exercise and practice. Long-time sport is easy to generate tenosynovitis and spur hyperplasia disease; And in the process of gymnastics, the neck injury is often caused because of the accident, such as in 1998 the Chinese gymnastics player was with sixth, seventh cervical spine fracture injury because unfortunately falls during the match. In recent years, in the National Gymnastics Championships, the Zhejiang athletes Wang Yan caused the second, third cervical fracture dislocation because of the head down to the ground [9]. In many cases, the trauma of sports is not only a simple physical injury to athletes, and even directly endangers the lives of athletes in many cases. Therefore, in the process of the sports training, sports competitions and other activities, the athletes need to strengthen the protection work in the process of movement, and medical imaging techniques should be used for the diagnosis of trauma in the course of the movement, and the treatment should be carried out in time according to the

diagnosis. Table 1 shows some of the injuries occurring for specific sports.

Table 1. Sports related injuries and occupational diseases.

Sport event	Related sports injuries
Shooting	Cervical spondylitis, waist
Table Tennis	Shoulder injury, cervical spondylosis, knee injury
Archery	Yellow heart disease
Weightlifting	Lumbar muscle strain
Swimming	Swimming shoulder and leg
Badminton	A sore knee, ankle injury
Artistic Gymnastics	Cervical vertebra fracture
Diving	Retinal injury

In recent years, the damage of athletes in our country becomes more and more serious. Due to multiple injuries, many athletes have a long illness trauma, which have long plagued the athletes' physical and mental [10]. Take a case study on the injuries of athletes in a sport in our country for example, through the investigation of active players and retired members of 72 athletes, most of them have the case of injury, and the maximum injured number is reached 12 times. The specific situation is shown in Table 2.

Table 2. Injury of a sports athlete in our country.

Team member	Total number	Number injuries	of	Number of injuries	Per number injuries	capita of
Retired players	42	41		291	7.1	
Active member	30	30		159	5.3	

The characteristics and causes discussion of sports injuries

Nowadays, due to the popularity of sports and the constant exploration of the new action, now development of sports injuries is toward the younger age, especially in gymnastics, diving and other art and sports. For older athletes, chronic injury is the major sports injury, and acute sports injury is the major sports injury for the relatively young players [11]. In terms of physical injury, the people with long-term exercise most likely to cause physical damage to the joints, such as the knee, waist, cervical spine, etc. Because the long-time sports action feature makes a certain part of a joint need a larger and stronger support power, it will inevitably cause damage to joints. Take the neck injury, for example, the main neck injury is the neck and neck soft tissue injury. The neck injury perennial will further lead to cervical spondylosis or cervical myofascitis, bringing longer pain to athletes. For the foot deformation, the common deformation occurred in the toe, ankle and calcaneus, bone. Take gymnastics as an example, the

long running and jumping cause serious foot deformation, and these deformations will bring great pain.

There are many factors that cause sports injuries, including internal and external factors. Both subjective and objective factors exist, factor analysis is often not just a factor, but a number of factors common cause the trauma. In terms of the athlete's own factors, that warm-up before the exercise is not enough and the preparation is not reasonable will cause trauma because the muscle or bone is not open in the movement [12]. Athletes in low spirits caused by various reasons will also cause some impact on the movement of the athletes, such as their attention is not concentrated in the process of movement, energy dispersion, etc. After being injured, some athletes or coaches do not cause enough attention, and there is no timely treatment and treatment of injuries, resulting in increased damage and latent. Coupled with the athletes of long time accumulation, it leads to pain, and old wounds healed wound again. In the case that some athletes are not familiar with the technical movement, they are in a rush to strengthen the exercise load, improve their own movement difficulty, resulting in the probability of the occurrence of the accident, and thus leading to the occurrence of sports injuries [13]. The physical quality of the athletes themselves will have a great impact on the movement process. Many people have long time training and are tired in the training process, which leads to the increase in errors. According to the analysis of the factors of injury of athletes, the specific situation is shown in Table 3.

Table 3. Injury of a sports athlete in our country.

Serial number	Cause of injury
1	Poor physical quality
2	Technical essentials is not correct
3	Be absent-minded
4	With training and competition
5	Be down in spirits
6	Inadequate preparation activities
7	Physical fatigue
8	Poor physical strength
9	Excessive excitement
10	Old wounds healed
11	Action is too difficult
12	Technical mastery is not good enough
13	Objective location and climatic factors
14	Training in the treatment of injury for a timely manner
15	Poor awareness of self-protection
16	In a training match

According to the different human body tissue, the parts and tissues subject to the trauma can be divided into six major

categories: skin and subcutaneous soft tissue, bone and cartilage, tendons and ligaments, joints and muscles, and peripheral nerve. No matter what part or tissue is damaged, it is needed to be diagnosed and treated in a timely manner. Only the timely diagnosis and treatment can prevent the expansion of the trauma and the deterioration of the injury in the shortest time, and provide accurate and reliable medical imaging evaluation for the treatment of injured athletes [14]. Commonly used medical imaging technology has MRI, CT, X-ray image, ultrasound technology, etc. In order to obtain a more accurate trauma, two and more medical imaging techniques are adopted to evaluate some sports injuries.

Medical Imaging Technology Diagnosis of Sports Injuries

Ultrasound diagnosis

The principle of ultrasound diagnosis is that according to the different acoustic impedance caused by different density of different human tissues, when the incident ultrasonic waves enter into body tissues or organs, the acoustic impedance difference will occur, and if the acoustic impedance value is greater than 0.1, the phenomena of refraction and reflection will appear in two different density between organizations. When sound waves travel through different organizations, the acoustic interface will show a large difference in the echo. The internal fine structure of the tissue and the organ can be displayed through the echo, so as to make an accurate judgment of the functional state, morphological structure and physical characteristics of the tissue or organ, and make the clinical diagnosis [15]. The specific working principle of ultrasonic diagnosis is shown in Figure 2. Using ultrasound to assess the medical images, which has a high resolution of muscle, ligament and blood vessel, can carry out real-time dynamic monitoring in the whole course, timely observation and understanding of the extent of trauma and treatment effect [16]. In practical medical practice, ultrasound is mainly used for imaging diagnosis of visceral lesions, and it is often used in gynecological examination because of its harmful characteristics. And the imaging examination effect of joint trauma of athletes using ultrasound examination is also good, throughout the whole process of the diagnosis, treatment and rehabilitation of the whole process.

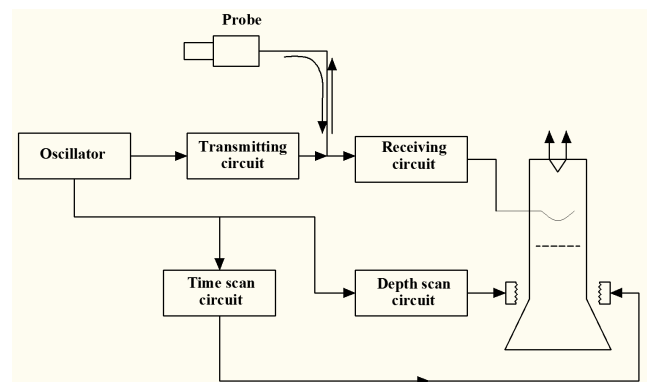


Figure 2. Principle of ultrasonic imaging system (M).

Sports injuries are mainly characterized by soft tissue injury. In the diagnosis of the injury, expect for the clinical function inspection, palpation and percussion, ultrasonography can provide an accurate and objective basis for the diagnosis of sound image diagnosis. This diagnosis includes the diagnosis and examination of muscle fascia injury, tendon injury, ligament injury, meniscus injury, articular cartilage and bone fracture, which has considerable value for the diagnosis of sports injuries.

X ray radiography

Because the density of human tissue has a larger difference with its thickness, when the penetration of X-rays through the human body is projected onto the film, the amount of X-ray has great differences because of differences in human tissues, so as to form the image data of chiaroscuro [17]. Compared with CT and MRI technology, X-ray imaging technology has the characteristics of simple, fast and the dropping of the image, which image is the simple and direct, easy analysis and understanding, plays a very important role in the initial diagnosis of sports injury. It has a very prominent advantage in the micro fracture of sports trauma, cervical spinal cord injury and so on. It is widely used in clinical diagnosis, and its working principle is shown in Figure 3. However, due to when using X-ray through the body tissue, it is absorbed more by the human body, and the clarity of medical image made by the difference between the X-ray volume on the screen is not enough, and cannot be dynamic observation.

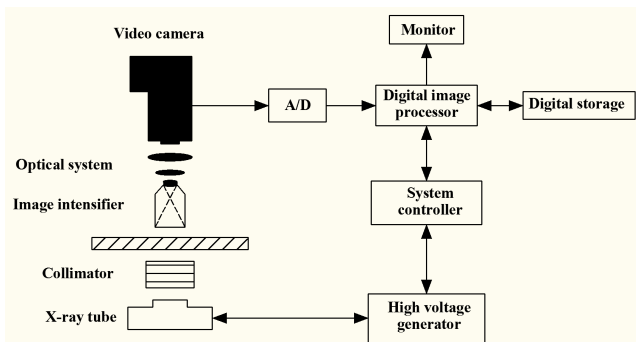


Figure 3. Principle of X-ray imaging system.

MRI imaging technology

For cervical spinal cord injury caused by sports injuries, the results of MRI examination are better. This kind of injury is generally more complex, difficult to deal with, poor prognosis, and when the condition is serious, it even may endanger the life of athletes, causing serious complications [18]. MRI imaging technology is magnetic resonance imaging, using the phenomenon of magnetic resonance, and the extraction of human electromagnetic signal for reconstruction. Because the MRI technology can be used in different directions to scan and get the image of the fault, so the three-dimensional and even four-dimensional images can be reconstructed, and the principle of imaging is shown in Figure 4. At present, the

technology is widely used in various fields of physics, biology, chemistry and so on, and commonly used in medicine is the nucleus of a hydrogen atom. With the strength of magnetic resonance signal intensity, MRI imaging will be reflected above the gray, and the stronger the signal, the image is bright. When the flow liquid is encountered, the blood vessel is rendered as a gray and white tubular structure on the image because of the flow blank effect. Using MRI technology can carry on the imaging diagnosis of the brain, the joint skeleton, the soft tissue and so on. For acute spinal cord injury in sports injury, MRI is used to understand the situation of spinal cord injury, spinal cord water will show swelling and thickening, the spinal cord edema and bleeding will appear in spinal cord injury, and the signal will be enhanced [19]. MRI can show the various details of the spinal cord, soft tissue and ligament injury, clear vertebrae damage, which is the ideal inspection method of spine injury.

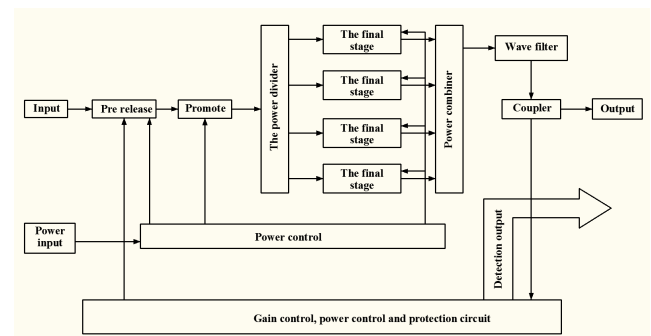


Figure 4. Working principle of MRI imaging system.

But MRI also has many deficiencies, and for lung, gastrointestinal tract examination, it is not as good as other inspection methods. When the human body is left with metal items, such as when the body is installed with a pacemaker, it is not suitable for MRI imaging, and pregnant women and critically ill patients are not suitable for inspection. Therefore, it is more suitable to the diagnosis and examination of sports injuries of the chest, bone and joint and the soft tissues of the whole body, and the results are relatively accurate.

CT imaging

CT imaging uses that a continuous section scanning of a part or tissue of a human body is made by a detector, and reconstruction of tissue images by scanning data is conducted. Because the X-ray absorption and the transmission rate of different tissues of the human body is not the same, so when the data is scanned, the data is then entered into the electronic computer for processing. Use the processed data for image reconstruction, and find the lesion or tissue damage of the body. As a result of the use of CT scanning is a fault scan, and thus it needs to be consistent in the direction of transection [20]. CT equipment consists of three main parts, computer system, X-ray tube and detector, image display and storage system, and the specific working principle is shown in Figure 5. The image density resolution which is scanned by CT is higher, and even if the density difference is small in the human

body tissue, it can also form contrast imaging. The organs composed by soft tissue such as brain, spinal cord, and lung can be better displayed, and the lesion image can be displayed on the background of the anatomical image.

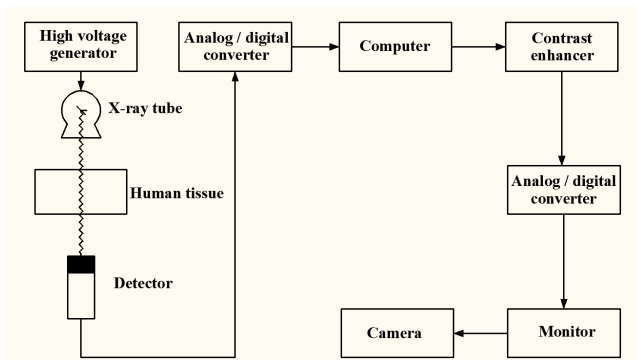


Figure 5. Working principle of CT imaging system.

CT examination is more used in central nervous system related diseases, such as intracranial tumors, cerebral hemorrhage, cerebral infarction and other diseases. But it also has high diagnostic value for the head and neck diseases, and in the related examination of chest, large blood vessels and heart, the effect of the image data is better. But for the image of the bone and joint scanning, the use of CT is relatively small. Compared to X-ray, the machine radiation dose is larger in the use of CT, so pregnant women should not be with CT.

Trauma Diagnosis of Basketball Players Based on Medical Imaging Technology

Data

The object of this study is 77 basketball players in one province of China in 2015, of which 41 male athletes, 36 female athletes, the average age of male athletes is at the age of 24.1, and the average age of female athletes is at the age of 21.9. It can be seen through the training resume analysis of basketball that the average age at the beginning of training of the male players is in the 8.17 years old, the number of years in the 5-26 years, an average of 8.3 years; the average age at the beginning of the female players is in the age of 9.73 years, the number of years in the 2-27 years, an average of 5.1 years. It can be seen from the further analysis of the athletes that the sports level is as follows: There are 32 first class athletes, 23 for the second class athletes, 14 for the third class athletes, and there are 8 players who are not rated. Their cultural level is as follows: There is one graduate or above, 44 for bachelor degree, 26 for major secondary school education, and there are 6 for high school and below.

Research methods

In the study, the basketball athletes are studied to understand the basic information and data, communicate with the doctor, so as to master the basic physical condition of every athlete. All the relevant information of the athletes is only used in this study, not the specific content for others to use. After

understanding of the athletes' initial physical condition, the specific physical examination of the athletes is carried out. For the bone and joint injury of the athletes, X-ray examination is firstly considered, and if necessary, it should take the sound wave, CT or MRI check. All diagnostic imaging data are backed up in order to carry out specific research. And the image data will be communicated with athletes and doctors, and make mutual confirmation of clinical manifestations. Statistics for sports injuries should be in accordance with the number of person, and it does not divide the specific acute and chronic injury in statistical process. For athletes who have performed surgery or need to carry out surgery, they are conducted with statistics, respectively. Especially for the athletes such as dislocation of joint and tendon rupture, it should ensure the accuracy of the image. During the period of 2015, the research content mainly uses medical imaging technology for the diagnosis of sports trauma, and statistics and description of the composition of the disease are carried out.

Results and Discussion

Through statistical research, among the 77 basketball players in the province, a total of 71 sports have sport injuries, with the percentage of 92.2%, of which there are 38 men and 33 women, and the prevalence rate are, respectively, 92.7% and 91.7%. It can be seen that there is no significant difference between male and female athletes in the gender. According to the nature of acute and chronic trauma to classify, among the 71 athletes who have sports injuries, the total cumulative damage is 142 times, including acute injury in 48 cases, accounting for 33.8% of the total cases, chronic 41 cases, accounting for 28.9% of the total cases, 43 cases for acute to chronic injury with 37.3%. The specific circumstances are shown in Table 4.

Table 4. Injury of a sports athlete in our country.

Prevalence rate		
Gender	Number	Prevalence rate
Male	38	92.70%
Female	33	91.70%
Trauma nature		
Trauma nature	Number of trauma cases	Proportion
Acute	48	33.80%
Chronic	41	28.90%
Acute to chronic	43	37.30%

According to the classification statistical analysis of common sports injury in basketball sports, namely fracture, dislocation of the joint, ligament rupture and tendon rupture of these four kinds (Table 5). According to the image analysis and statistics, the following results are obtained: (1) There were 10 cases of fractures in 2015, 8 cases of the previous fracture occurred in 2015; (2) There were 2 cases of joint dislocation during 2015, 3 cases of anterior dislocation occurred in 2015; (3) There were

5 cases of ligament rupture during the period of 2015, and 11 cases of rupture of the anterior ligament in 2015; (4) There were 3 cases of tendon rupture during 2015, and 2 cases of rupture of tendon before 2015.

Table 5. Statistical analysis of athletes' sports injuries in 2015 and 2015 years ago.

S.no	Name of disease	2015 onset	Onset before 2015	Total
1	Fracture			
1.1	Nasal bone fracture	3	2	5
1.2	The fifth metatarsal fatigue fracture	1	1	2
1.3	Fracture of scaphoid bone	2	1	3
1.4	Fatigue fracture of tibia	1	1	2
1.5	Readings of metacarpal fractures	1	2	3
1.6	Lumbar vertebral pedicle fracture	2	1	3
2	Dislocation of joint			
2.1	Dislocation of joint	2	3	5
3	Rupture of ligament			
3.1	Fracture of anterior cruciate ligament of knee joint	3	9	12
3.2	Fracture of medial collateral ligament of knee joint	1	1	2
3.3	Fracture of posterior cruciate ligament of knee joint	0	1	1
3.4	Small fingers collateral ligament	1	0	1
4	Rupture of tendon			
4.1	Finger extensor tendon rupture	1	1	2
4.2	Rupture of Achilles tendon	2	1	3

Through statistical analysis, it can be seen that the most common sports injury of basketball players is fracture, and the second is ligament rupture. This is due to the special nature of the basketball sport itself, the strength of the movement is also large, and there are many physical conflicts. At the same time, it also shows that the sports injury of basketball players is more common, and most people have sports injuries. Using medical imaging technology, the diagnosis of sports injuries of athletes is reliable, and it is helpful for the follow-up treatment.

Conclusion

Medical imaging technology is widely used in sports injuries, and has a certain guiding role in the treatment of sports injuries. Whether the ultrasound diagnosis, X-ray radiography or CT imaging, are based on the different density of the human body tissue and the different absorption of scanning X-ray imaging to form images, and MRI imaging technology is using nuclear magnetic resonance imaging. These four kinds of medical imaging technology have different advantages and

disadvantages, and can be applied to different diagnosis of trauma. For further application of medical imaging technology in the diagnosis of sports injury, basketball players in one province of China in 2015 are used as the research object for analysis and statistics of sports injuries respectively in 2015 and before, in order to understand the basketball players' physical condition and help the follow-up treatment. For the initial diagnosis of basketball players, medical imaging technology are used, and the X-ray examination should be firstly considered. If necessary, the sound wave, CT or MRI check can be taken. Through statistical research, it can be seen that there are more injuries of the basketball players in the fracture and ligament rupture, and the use of medical imaging technology can be reliable for the diagnosis of sports trauma.

Acknowledgement

The presented work is financially supported by the Youth Talent Project of Higher Education Institutions of Beijing (YETP1713); General Program of Science and Technology Development Project of Beijing Municipal Education Commission (SQKM201610029004), which is gratefully acknowledged.

References

1. Dmitrovic S. Specific injuries in wrestling and physiotherapy procedures for prevention and rehabilitation. Zdravstveno Veleucilište 2015.
2. Smethurst T. Playing with trauma in video games: interactivity, empathy, perpetration. Ghent University 2015.
3. Soligard T, Steffen K, Palmer-Green D, Aubry M, Grant ME. Sports injuries and illnesses in the Sochi 2014 Olympic Winter Games. Br J Sports Med 2015; 49: 441-447.
4. Gjorgjievskaja S. Basic Trauma Life Support in non-Urban Setting. Sveucilište u Zagrebu 2015.
5. Wang F, Chen Z, Pan S. Sports injuries and illnesses during the 2008 Olympic Games and 2013 China National Games in Shenyang Division. Zhonghua Yi Xue Za Zhi 2015; 95: 1285-1289.
6. Glaudemans AWJM, Dierckx RAJO, Gielen JL, Zwerver J (Eds.). Nuclear Medicine and Radiologic Imaging in Sports Injuries. Springer, Berlin, Heidelberg, 2015.
7. Noordzij W. Nuclear medicine imaging techniques. Nuclear Med Radiol Imaging Sports Injuries 2015.
8. Serner A, Tol JL, Jomaah N, Weir A, Whiteley R. Diagnosis of Acute Groin Injuries: A Prospective Study of 110 Athletes. Am J Sports Med 2015; 43: 1857-1864.
9. Rebolledo BJ, Nwachukwu BU, Konin GP. Posterior Humeral Avulsion of the Glenohumeral Ligament and Associated Injuries: Assessment Using Magnetic Resonance Imaging. Am J Sports Med 2015; 43: 2913-2917.
10. Grobterlinden LG, Hartel M, Yamamura J. Isolated syndesmotic injuries in acute ankle sprains: diagnostic

- significance of clinical examination and MRI. *Knee Surgery Sports Traumatol Arthroscopy* 2015; 94: 1-7.
11. Balanika A, Papakonstantinou O, Chatzimichael E. Muscle injuries in athletes during the olympic games of Athens 2004: Imaging with US and MR 2015.
 12. Hayashi D, Scheepers S, Guermazi A. Multimodality imaging of upper and lower extremity injuries in triathlon - a pictorial review. *European Congress of Radiology* 2014.
 13. Maroon JC. Handbook of neurological sports medicine concussion and other nervous system injuries in the athlete. *Surgical Neurol Int* 2015; 6: 7-13.
 14. Riley GM. Magnetic resonance imaging in the evaluation of sports injuries of the foot and ankle: a pictorial essay. *J Am Podiatric Med Association* 2007; 97: 59-67.
 15. Musyoka NM, Petrik LF, Hums E. In situ ultrasonic diagnostic of zeolite X crystallization with novel (hierarchical) morphology from coal fly ash. *Ultrasonics* 2013; 54: 537-543.
 16. Ubukata H, Maruyama H, Huo M. Reliability of measuring pelvic floor elevation with a diagnostic ultrasonic imaging device. *J Phys Ther Sci* 2015; 27: 2495-2497.
 17. Guizarsicairos M, Boon JJ, Mader K. Quantitative interior x-ray nanotomography by a hybrid imaging technique. *Optica* 2015; 2: 259-266.
 18. Schenberg T. MRI screening for breast cancer in women at high risk in the Australian breast MRI screening access program addressing the needs of women at high risk of breast cancer?. *J Med Radiation Sci* 2015; 62: 212-225.
 19. Metzner R, Eggert A, van Dusschoten D, Pflugfelder D, Gerth S. Direct comparison of MRI and X-ray CT technologies for 3D imaging of root systems in soil: potential and challenges for root trait quantification. *Plant Methods* 2015; 11: 17.
 20. Meyer MG, Hayenga JW, Neumann T, Katdare R, Presley C, Steinhauer DE, Bell TM, Lancaster CA, Nelson AC. The Cell-CT 3-dimensional cell imaging technology platform enables the detection of lung cancer using the noninvasive LuCED sputum test. *Cancer Cytopathol* 2015; 123: 512-523.

***Correspondence to**

Sihua Li

Capital University of Physical Education and Sports

Beijing

PR China