

## **Clinical diagnosis and treatment of peripherally inserted central catheter related upper extremity deep venous thrombosis.**

**Xuming Bai<sup>1#</sup>, Xingshi Gu<sup>1#</sup>, Long Cheng<sup>1#</sup>, Qiang Yuan<sup>1</sup>, Jian Jing<sup>1</sup>, Yinfen Jiang<sup>3</sup>, Yong Jin<sup>1\*</sup>, Chungeng Xing<sup>2\*</sup>**

<sup>1</sup>Department of Interventional Radiology, the Second Affiliated Hospital of Soochow University, Suzhou, PR China

<sup>2</sup>Department of General Surgery, the Second Affiliated Hospital of Soochow University, Suzhou, PR China

<sup>3</sup>Nursing Department, the Second Affiliated Hospital of Soochow University, Suzhou, Jiangsu, PR China

#These authors contributed equally to this work

### **Abstract**

**Objective:** This study aimed to investigate clinical diagnosis and treatment of Peripherally Inserted Central Catheter (PICC) related deep vein thrombosis.

**Materials and methods:** A retrospective study was performed for 19 cases of patients with concurrent upper extremity deep vein thrombosis after inserting PICC from August 2011 to December 2014 in our hospital.

**Results:** There were 8 cases and 11 cases with PICC in the right upper extremity and left upper extremity, respectively. All 19 cases had swelling of the upper extremities and discomfort after activity, and 18 cases had varying degrees of pain after activity. By ultrasonography 18 cases were diagnosed with deep vein thrombosis and 1 case with suspected deep vein thrombosis. All 19 patients underwent the indwelling thrombolysis catheter-directed thrombolysis based on anticoagulation therapy, thrombolysis time was 2-6 ( $3.16 \pm 1.10$  d), including 16 cases (89%) at grade III thrombolysis and 3 cases (11%) at grade II thrombolysis. 17 patients (89.5%) were clinically recovered and 2 cases (10.5%) were improved, with a total efficiency of 100%. No serious complication was noticed during thrombolysis. After thrombolysis, four cases were diagnosed as phlebostenosis and received stent implantation treatment. During follow-up of 6-36 months, no cases had recurred thrombosis and post-thrombotic syndrome.

**Conclusion:** PICC related deep vein thrombosis could be diagnosed by color Doppler ultrasonic with venography as a supplement. Catheter-directed thrombolysis technique is characterized by short thrombolysis time, safety and efficiency for the treatment of C related deep vein thrombosis.

**Keywords:** Upper extremity, Venous thrombosis, Peripherally inserted central catheter, Thrombolysis.

*Accepted on October 3, 2017*

### **Introduction**

Peripherally Inserted Central Catheter (PICC) is a kind of medium and long-term intravenous infusion treatment mainly used in patients with cancer, and has many advantages such as reducing vein puncture, achieving efficiency and being easily operated [1,2]. Generally, PICC could be approached into the pathway by puncture of upper arm superficial vein (such as basilic vein, cephalic vein) and then entered into and inserted in the deep vein to the superior vena cava. The Upper Extremity Deep Venous Thrombosis (UEDVT) is one of the most serious complications of PICC and is a challenge in the clinical [3,4]. Therefore, it is very important to investigate clinical diagnosis and treatment of PICC related UEDVT.

In this retrospective study, we enrolled 19 cases of PICC-related UEDVT patients admitted to our hospital from August 2011 to December 2014 and summarized our experience in the diagnosis and treatment of PICC-related UEDVT.

### **Subjects and Methods**

#### **Subjects**

19 cases of PICC-related UEDVT patients included 12 males and 7 females, aged from 23 to 78 years old, with the mean of  $53.59 \pm 12.93$  y old. Among them, 4 cases had primary gastric cancer disease, 3 cases had nasopharyngeal carcinoma, 3 cases had lung cancer, 2 cases had colon cancer, 3 cases had breast cancer, 1 case had non-Hodgkin's lymphoma, laryngeal

carcinoma, adenoid cystic carcinoma in external auditory canal, and testicular seminoma, respectively. There were 8 cases and 11 cases with PICC catheter inserted in the right extremity and left upper extremity, respectively. The main clinical manifestations: among 19 patients, 18 cases were with upper extremity swelling at affected side and varying degrees of pain. 19 cases were uncomfortable during activity. It took 1-7 d for the patients to receive treatment after the occurrence of the symptom, with the mean of  $2.29 \pm 1.46$  d.

### **Main auxiliary examination**

The D-dimers of 17 cases were elevated ( $>0.05 \mu\text{g/ml}$ ) and other 2 cases were normal. 19 patients underwent color Doppler ultrasonic and venography examination.

### **Treatment**

19 patients were requested to remove PICC catheter, and signed the informed consent form. The patients with anticoagulation and thrombolysis contraindication were excluded [5,6]. Before operation, the processing scheme for symptomatic pulmonary embolism occurrence was developed: real-time non-invasive pulse oxygen ECG monitoring was carried out during thrombolytic treatment period, if the pulse oxygen was below 80%. If the patients were accompanied with the difficulty in breathing, chest pain and other symptoms, thrombolysis was stopped and the rescue was carried out immediately. Pulmonary angiography was carried out along with related examinations and evaluations, if a large piece of thrombosis was noticed in the pulmonary artery. The thrombosis broking, aspiration, local thrombolysis and other treatments were also carried out.

19 patients underwent anticoagulation treatment with subcutaneous injection of dalteparin (5000 IU). The patients underwent Catheter-Directed Thrombolysis (CDT). The thrombolysis catheters were directly inserted in 13 cases, among them, 9 patients were with PICC catheters entered by the method of inserting 0.018 inch guide wires to exchange PICC catheters. Next they were entered into the catheter sheath and then the 4 F single-bending super-smooth catheters were entered *via* the sheath. The exchange guide wire was 0.035 inch guide wire to help the insertion of thrombolysis catheters. Four cases were with thrombolysis catheters inserted by color Doppler ultrasound-guided punctures of elbow basilic vein ( $n=1$ ) and brachial vein ( $n=3$ ). The thrombolysis catheters were inversely inserted in 6 cases (*via* femoral vein approaching pathway). The thrombolysis catheter with appropriate hole segment length scope at catheter side (10 cm, 20 cm, Angiodynamics, USA) were selected according to the scope of thrombosis. 250 ml saline and 200,000 U urokinase were used and pumped *via* thrombolysis catheter by intelligent intravenous infusion pump and then maintained for 4 h twice daily [6]. For the patients who had no thrombolysis contraindications, the amount of urokinase was reduced by half. The clotting mechanism was monitored during the thrombolysis, including Prothrombin Time (PT), Activated Partial Thromboplastin Time (APTT), Thrombin Time (TT),

Fibrinogen (FIB), International Normalized Ratio (INR) and Platelet (PLT), once a day. The angiography re-examination was done *via* thrombolysis catheter with an interval of 24-48 h after the start of thrombolysis. Furthermore, the thrombolysis catheter position and thrombolysis scheme were adjusted according to the results: (1) if the thrombosis was completely dissolved, the thrombolysis was stopped; (2) if the thrombosis was partially dissolved, the thrombolysis was continued; (3) after all or most of the thrombosis was dissolved, if there was the stenosis ( $>50\%$ ), the balloon dilatation and/or stenting implantation was carried out, followed by the angiography after one day's continuous thrombolysis. During the thrombolysis process, the affected extremities of patients were less moved. After thrombolysis treatment, anticoagulation treatment continued for 6-12 months with warfarin dose adjusted according to the INR (2.0-3.0). Those with stent implantation took warfarin for a long term and the blood clotting was regularly monitored.

## **Results**

### **Diagnosis of PICC-related deep vein thrombosis**

All 19 cases were diagnosed with PICC-related deep vein thrombosis *via* angiography. The sites of thrombosis included 7 cases at the right axillary vein+subclavian vein, 1 case at right subclavian vein+brachiocephalic vein, 10 cases at left axillary vein+subclavian vein, and 1 case at the left brachiocephalic vein. All 19 cases were non-floating thrombosis, and 2 cases involved a small part of the brachiocephalic vein (not more than 1/4 of brachiocephalic vein). By ultrasonography 18 cases were diagnosed with PICC related ULDVT thrombosis (Figure 1), and 1 case was diagnosed with suspicious brachiocephalic vein thrombosis. Ultrasonic showed that the coincidence rate of axillary vein thrombosis and angiography was 100% (17/17 patients), and the ultrasonic showed poorly for the subclavian vein and brachiocephalic vein thrombosis.

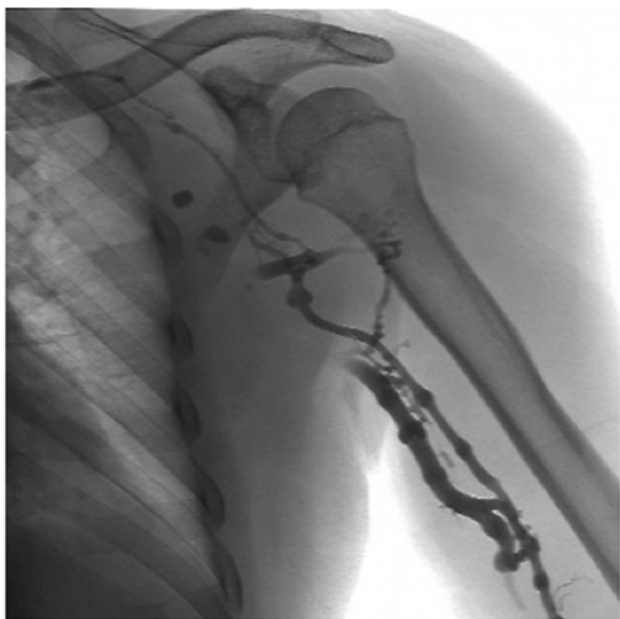### **Thrombolysis treatment**

Thrombolysis treatment course was 2-6 d (mean  $3.16 \pm 1.10$  d). In 16 cases, thrombolysis reached grade III (indicating that the thrombosis had been completely dissolved). In 3 cases, thrombolysis reached grade II (indicating that most of the thrombosis were dissolved).

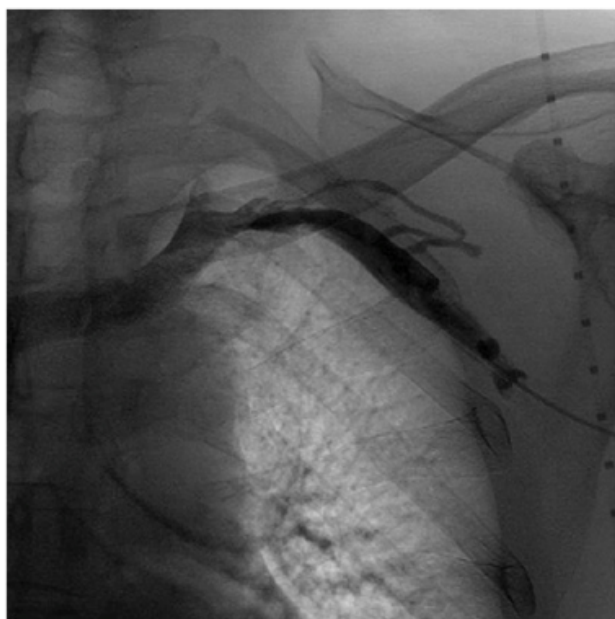
Four cases had vein stenosis balloon dilatation after thrombolysis and received stent implantation (Figure 2). For clinical efficacy, 17 cases were cured and 2 cases were improved, indicating the total efficiency of 100%. For complications, 5 cases had mild bleeding at the edge of the inserted catheter sheath, but no any case had symptomatic pulmonary embolism, hemorrhage of gastrointestinal tract, urinary tract or the brain, or infection and other complications caused by catheter inserting.

### **Follow-up**

The 19 patients were followed for 6-36 months (mean 13.06 ± 11.22 months). Among them, 14 patients died of the primary tumor and associated complications in 6-20 months. During the follow-up, the swelling, pain and other symptoms at the affected extremities disappeared in all patients and they were not uncomfortable when moving, and there were no varicosity or other reflux disorder symptoms. Ultrasonic examination showed that there was no recurrence or progression of thrombosis and the deep vein valve function was normal.



**Figure 1.** The patient was a male 23 y old. His testicular seminoma was under chemotherapy, the left PICC had been inserted for two weeks and the left upper limb had been under swelling for two days.



**Figure 2.** The balloon dilatation stenosis was still >50% and the stent implantation were performed.

### **Discussion**

ULDVT has been relatively rare in the past, but the incidence is increasing recently [7,8]. This could be due to several factors such as catheter material, inserting pathway, operational factor, lying in bed, high-coagulation physical condition, chemotherapeutic drug [9-11].

Early ULDVT could be completely asymptomatic, and then clinical symptoms develop such as extremity swelling, pain, serious discomfort, increased skin temperature, skin color change and venous engorgement. Approximately 20-66% of patients have these symptoms but are not diagnosed [12-14]. For the diagnosis of PICC-related ULDVT, color Doppler ultrasound could achieve the sensitivity and specificity of up to 100% and 93%, respectively [7]. Venography is the gold standard for ULDVT diagnosis, but it is invasive and costly and thus not suitable as a routine screening diagnosis. Instead, ultrasound examination is a preferred choice. In this study, the coincidence rate of color Doppler ultrasonic diagnosis and venography was 18/19, 1 patient had thrombus in the left brachiocephalic vein and got suspicious diagnosis by ultrasonic but confirmed diagnosis by angiography.

For PICC-related ULDVT, the anticoagulant is a common method of treatment. Since PICC related ULDVT is mainly related to catheter material, tumor and vascular stenosis, it is generally believed that the catheter should be removed [15]. Most scholars suggest adopting thrombolytic therapy for ULDVT thrombus clearance, the ideal thrombolysis model is to maximize the thrombolysis and avoid the risk of bleeding, but traditional systemic thrombolysis applies thrombolytic drugs into peripheral vein body [16]. In contrast, during CDT thrombolysis catheter is inserted into thrombus, the thrombolytic drugs can be directly infused to the thrombus, increasing local concentration of thrombolytic drugs while reducing systemic drug dosage. A recent CDT randomized study showed that CDT could increase the opening degree of the responsible vein of DVT, the bleeding risk of thrombolysis and the long-term deep vein Post-Thrombotic Syndrome (PTS) could be significantly reduced [17].

CDT has become the recommended treatment measure for DVT [18,19]. Since DVT occurs mainly in the lower extremities, CDT is mainly used in lower extremity DVT. For ULDVT treatment, traditional systemic thrombolysis is mostly still used, the improvement rate is about 70% and PST rate is about 15% [20-22]. In this study, 19 patients received CDT and the clinical cure rate was 89.5% (17/19). The improvement rate was 10.5% (2/19), and no PTS occurred during follow-up. Compared with systemic thrombolysis, CDT in this study had the following characteristics: the total utilization of urokinase was low, the thrombolysis time was short, the clinical efficacy was high and no serious complication occurred, consistent with the characteristics of CDT for the treatment of the lower extremity DVT. Therefore, we propose the use of CDT for the treatment of PICC related ULDVT.

Whether the superior vena cava filter needs to be placed on PICC related ULDVT to prevent pulmonary embolism has not

been determined [23,24]. Based on our experience, for PICC related ULDVT treatment, the use of the superior vena cava filter should be strictly grasped. In the absence of filter protection, during the removal and inserting of catheter the pulmonary embolism rescue should be fully prepared, real-time monitoring and gentle operation should be taken, close monitoring should be carried out on the ECG pulse oxygen and vital signs and the limb movement should be reduced during the thrombolysis.

For the diagnosis and treatment of PICC related ULDVT, our experience is as follows: color Doppler ultrasound examination is the preferred choice and the venography is taken as a supplement means; based on the anticoagulation, the thrombolysis should be carried out as soon as possible; the trauma will be minimized after direct thrombolysis by applying angiography and exchanging and inserting thrombolysis catheter while removing PICC. CDT is characterized by short treatment course, better efficacy, fewer adverse reactions, better safety and feasibility.

### Acknowledgements

This study was supported by the grants from Natural Science Foundation of China (No. 81172348), Suzhou Key Medical Center (No. LCZX201505), Jiangsu Province Clinical Medical Science and Technology Program (No. BL2013016) and Preponderant Clinic Discipline Group Project Fund of the second affiliated Hospital of Soochow University.

### Disclosure of Conflict of Interest

None

### References

1. Ng PK, Ault MJ, Ellrodt AG, Maldonado L. Peripherally inserted central catheters in general medicine. *Mayo Clin Proc* 1997; 72: 225-233.
2. Tian G, Zhu Y, Qi L, Guo F, Xu H. Efficacy of multifaceted interventions in reducing complications of peripherally inserted central catheter in adult oncology patients. *Support Care Cancer* 2010; 18: 1293-1298.
3. Turcotte S, Dube S, Beauchamp G. Peripherally inserted central venous catheters are not superior to central venous catheters in the acute care of surgical patients on the ward. *World J Surg* 2006; 30: 1605-1619.
4. Amerasekera SS, Jones CM, Patel R, Cleasby MJ. Imaging of the complications of peripherally inserted central venous catheters. *Clin Radiol* 2009; 64: 832-840.
5. Vascular Surgery Group of Society of Surgery of Chinese Medical Association. *Diagnosis and Treatment Guidelines of Deep Venous Thrombosis*. Chinese J Gene Surg 2008; 23: 235-238.
6. Mewissen MW, Seabrook GR, Meissner MH, Cynamon J, Labropoulos N, Houghton SH. Catheter directed thrombolysis for lower extremity deep venous thrombosis:

report of a national multicenter registry. *Radiology* 1999; 211: 39-49.

7. Blaiwas M, Stefanidis K, Nanas S. Sonographic and clinical features of upper extremity deep venous thrombosis in critical care patients. *Crit Care Res Pract* 2012; 2012: 489135.
8. Evans RS, Sharp JH, Linford LH. Risk of symptomatic DVT associated with peripherally inserted central catheters. *Chest* 2010; 138: 803-810.
9. Seeley MA, Santiago M, Shott S. Prediction tool for thrombi associated with peripherally inserted central catheters. *J Infus Nurs* 2007; 30: 280-286.
10. Spencer FA, Emery C, Lessard D, Goldberg RJ, Worcester Venous Thromboembolism Study Group. Upper extremity deep vein thrombosis: a community-based perspective. *Am J Med* 2007; 120: 678-684.
11. King MM, Rasnake MS, Rodriguez RG, Riley NJ, Stamm JA. Peripherally inserted central venous catheter associated thrombosis: retrospective analysis of clinical risk factors in adult patients. *South Med J* 2006; 99: 1073-1077.
12. Bernardi E, Pesavento R, Prandoni P. Upper extremity deep venous thrombosis. *Semin Thromb Hemost* 2006; 32: 729-736.
13. Sud R, Khorana AA. Cancer-associated thrombosis: risk factors, candidate biomarkers and a risk model. *Thromb Res* 2009; 123: 18-21.
14. Shivakumar SP, Anderson DR, Couban S. Catheter-associated thrombosis in patients with malignancy. *J Clin Oncol* 2009; 27: 4858-4864.
15. Chaitowitz I, Heng R, Bell K. Managing peripherally inserted central catheter-related venous thrombosis: How I do it. *Australas Radiol* 2006; 50: 132-135.
16. Comerota AJ, Assi ZI. Catheter-based interventions for acute deep venous thrombosis. Rutherford RB. *Vascular Surgery* (6th edn.). Philadelphia WB Saunder 2005; 2181-2183.
17. Enden T, Haig Y, Klow NE. Long-term outcome after additional catheter-directed thrombolysis versus standard treatment for acute iliofemoral deep vein thrombosis (the CaVenT study): a randomised controlled trial. *Lancet* 2012; 379: 31-38.
18. Vascular Surgery Group of Society of Surgery of Chinese Medical Association. *Diagnosis and Treatment Guidelines of Deep Venous Thrombosis* (2nd Edn.). Chinese J Gene Surg 2012; 27: 605-607.
19. Geerts WH, Bergqvist D, Pineo GF. Prevention of venous thromboembolism: American College of Chest Physicians Evidence-Based Clinical Practice Guidelines (8th Edn.). *Chest* 2008; 133: 381-453.
20. Sun Y, Liu Y, Zhang SY, Jin X, Dong DN. Diagnosis and treatment of catheter-related upper extremity venous thrombosis. *Chinese J Curr Adv Gene Surg* 2011; 4: 273-276.
21. Feng ZC, Zhang H. Progress in Prevention and treatment of PICC-related venous thrombosis of tumor patients. *Chinese J Misdiagn* 2011; 11: 6325-6326.

*Clinical diagnosis and treatment of peripherally inserted central catheter related upper extremity deep venous thrombosis*

22. Elman EE, Kahn SR. The post-thrombotic syndrome after upper extremity deep venous thrombosis in adults: a systematic review. *Thromb Res* 2006; 117: 609-614.
23. Kearon C, Kahn S, Agnelli G. Antithrombotic therapy for venous thromboembolic disease: American College of Chest Physicians Evidence-Based Clinical Practice Guidelines (8th Edn.). *Chest* 2008; 133: 454-545.
24. Abdullah BJ, Mohammad N, Sangkar JV. Incidence of upper limb venous thrombosis associated with peripherally inserted central catheters (PICC). *Br J Radiol* 2005; 78: 596-600.

**\*Correspondence to**

Yong Jin

Department of Interventional Radiology

The Second Affiliated Hospital of Soochow University

PR China

Chungen Xing

Department of General Surgery

The Second Affiliated Hospital of Soochow University

PR China