

# Assessment of Uterine Abnormalities by Sonography

Aditya Kumar Mandal

Assistant Professor, Lord Buddha Kosi Medical College & Hospital, Saharsa, Bihar, India.

## Research Article

### Article Info:

Received on: 01/01/2016  
Accepted on: 15/02/2016  
Published on: 24/02/2016



QR Code for mobile

Literati



### ABSTRACT :

A uterine malformation is a type of female genital malformation resulting from an abnormal development of the Müllerian duct(s) during embryogenesis. Symptoms range from amenorrhea, infertility, recurrent pregnancy loss, and pain, to normal functioning depending on the nature of the defect.

Study was conducted for about the 12 month. In this duration the subjects between the age group of 18-48 years females were studied. The patients with pregnancy and having previous history of Hysterectomy was not considered for the study. Sampling technique adapted for the study as Complete Enumeration Method, Ultrasonography images are collected from radiology department, these images evaluated and subjected to statistical data analysis and results were analysed.

From the data in the 10 females congenital abnormalities were observed. In 5 females Arcuate uteri was seen. Bicornuate was seen in 3 Female and Agenesis is observed in 2 Females. When examining the various types of a uterine anomaly, the most common finding was bicornuate uterus; the second most common was septate uterus. In current study most common uterine abnormality is arcuate uterus.

**Keywords:** Uterine Abnormalities, Müllerian agenesis, Sonographic, Assessment.

## INTRODUCTION:

The reproductive function of the uterus is to accept a fertilized ovum which passes through the utero-tubal junction from the fallopian tube (uterine tube). It implants into the endometrium, and derives nourishment from blood vessels which develop exclusively for this purpose. The fertilized ovum becomes an embryo, attaches to a wall of the uterus, creates a placenta, and develops into a fetus (gestates) until childbirth. Due to anatomical barriers such as the pelvis, the uterus is pushed partially into the abdomen due to its expansion during pregnancy.

A uterine malformation is a type of female genital malformation resulting from an abnormal development of the Müllerian duct(s) during embryogenesis. Symptoms range from amenorrhea, infertility, recurrent pregnancy loss, and pain, to normal functioning depending on the nature of the defect.

The prevalence of uterine malformation is estimated to be 6.7% in the general population, slightly higher (7.3%) in the infertility population, and significantly higher in a population of women with a history of recurrent miscarriages (16%).

The most frequent uterine anomalies are those resulting from varying degrees of failure of fusion of the müllerian ducts. This variability makes classification difficult and de-

termination of the true incidence uncertain. Many of these malformations are detected by radiologic or sonographic studies. Estimates of incidence vary from 0.13% to 4.0%. The incidence of müllerian anomalies in patients with infertility has been reported to be as high as 6.3%.<sup>20</sup> Pregnancy occurs in many women despite these anomalies. The complication rates with pregnancy are considerably increased; complications include abortion, prematurity, postpartum hemorrhage, retained placenta, and breech presentation.<sup>21</sup> Not surprisingly, the rate of cesarean delivery is markedly higher<sup>[1]</sup>.

The American Fertility Society (now American Society of Reproductive Medicine) Classification distinguishes<sup>[2]</sup>:

- Class I: Müllerian agenesis (absent uterus)

Uterus is not present, vagina only rudimentary or absent. The condition is also called Mayer-Rokitansky-Kuster-Hauser syndrome. The patient with MRKH syndrome will have primary amenorrhea.

- Class II: Unicornuate uterus (a one-sided uterus)

Only one side of the Müllerian duct forms. The uterus has a typical "penis shape" on imaging systems.

- Class III: Uterus didelphys, also uterus didelphys (double uterus)

Both Müllerian ducts develop but fail to fuse, thus the pa-

\*Corresponding author:

Aditya Kumar Mandal

Assistant Professor, Lord Buddha Kosi Medical College & Hospital, Saharsa, Bihar, India.

doi: 10.15272/ajbps.v6i53.770

Conflict of interest: Authors reported none

submit your manuscript | [www.jbiopharm.com](http://www.jbiopharm.com)



tient has a “double uterus”. This may be a condition with a double cervix and a vaginal partition (v.i.), or the lower Müllerian system fused into its unpaired condition. See Triplet-birth with Uterus didelphys for a case of a woman having spontaneous birth in both wombs with twins.

- Class IV: Bicornuate uterus (uterus with two horns)

Only the upper part of that part of the Müllerian system that forms the uterus fails to fuse, thus the caudal part of the uterus is normal, the cranial part is bifurcated. The uterus is “heart-shaped”.

- Class V: Septated uterus (uterine septum or partition)

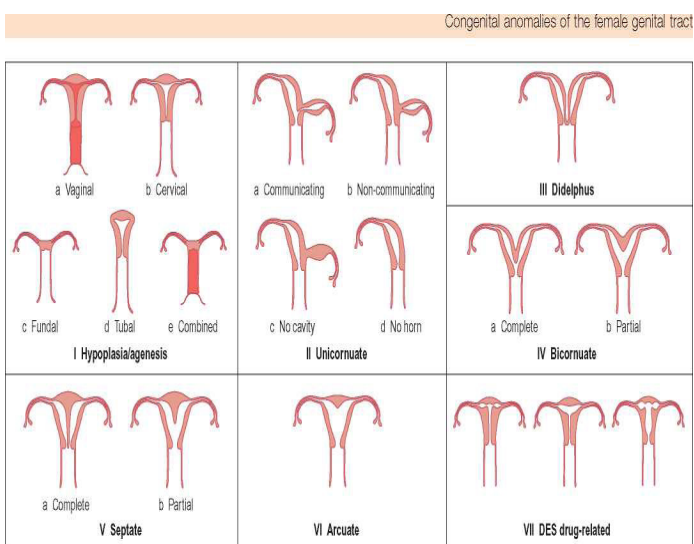
The two Müllerian ducts have fused, but the partition between them is still present, splitting the system into two parts. With a complete septum the vagina, cervix and the uterus can be partitioned. Usually the septum affects only the cranial part of the uterus. A uterine septum is the most common uterine malformation and a cause for miscarriages. It is diagnosed by medical image techniques, i.e. ultrasound or an MRI. MRI is considered the preferred modality due to its multiplanar capabilities as well as its ability to evaluate the uterine contour, junctional zone, and other pelvic anatomy. A hysterosalpingogram is not considered as useful due to the inability of the technique to evaluate the exterior contour of the uterus and distinguish between a bicornuate and septate uterus.

A uterine septum can be corrected by hysteroscopic surgery.

- Class VI: DES uterus.

The uterine cavity has a “T-shape” as a result of fetal exposure to diethylstilbestrol.

An additional variation is the arcuate uterus where there is a concave dimple in the uterine fundus within the cavity.



A rudimentary uterus is a uterine remnant not connected to cervix and vagina and may be found on the other side of an unicornuate uterus.

Patients with uterine abnormalities may have associated renal abnormalities including unilateral renal agenesis [3].

#### MATERIALS AND METHODS:-

Study was conducted for about the 12 month. In this duration the subjects between the age group of 18-48 years fe-

males were studied. The patients with Pregnancy and having previous history of Hysterectomy was not considered for the study. Sampling technique adapted for the study as Complete Enumeration Method, Ultrasonography images are collected from radiology Department, these images evaluated and subjected to statistical data analysis and results were analysed.

#### Inclusion Criteria:

- Age Group: 18- 48 years Females
- Pregnant Females
- Not having history of Hysterectomy

#### RESULTS AND DISCUSSION:-

In the study duration the numbers of pregnant women's were studied. From the data in the 10 females congenital abnormalities were observed. The congenital abnormalities were:

They are

|               |           |
|---------------|-----------|
| Arcuate uteri | 5 Females |
| Bicornuate    | 3 Females |
| Agenesis      | 2 Females |

#### 1. Agenesis:

Agenesis refers to the failure of an organ to develop during embryonic growth and development due to the absence of primordial tissue. Müllerian agenesis also is referred to as müllerian aplasia, Mayer–Rokitansky–Küster–Hauser syndrome, or vaginal agenesis. Given an incidence of 1 per 4,000–10,000 females, most general gynecologists will only encounter müllerian agenesis once or twice during their careers. Müllerian agenesis is caused by embryologic growth failure of the müllerian duct, with resultant agenesis or underdevelopment of the vagina, uterus, or both. The vaginal canal is absent or markedly shortened. A single midline uterine remnant may be present or uterine horns (with or without an endometrial cavity) can exist. The ovaries, given their separate embryologic source, are normal in structure and function [2].

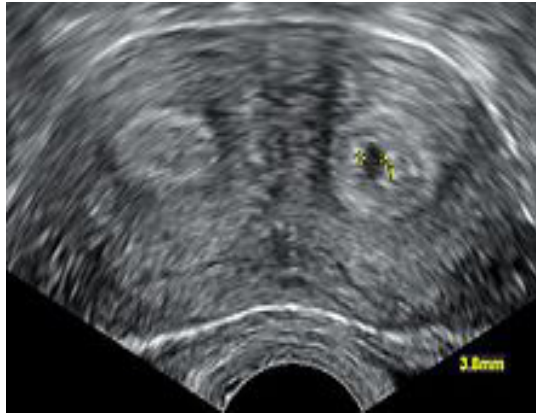The least common type of müllerian duct anomaly was found to be blind end vagina with absent uterus in girl with primary amenorrhea.

In the present study the Müllerian agenesis was found in 2 womens.

#### 2. Bicornuate

A bicornuate uterus or bicornate uterus, commonly referred to as a “heart-shaped” uterus, is a uterus composed of two “horns” separated by a septum. In humans, a bicornuate uterus is a type of uterine malformation, but in some other mammalian species, including rodents and pigs, it is normal. It can be classified as a class IV Müllerian duct anomaly.

In most cases, a bicornuate uterus is incidentally discovered when the pelvis is imaged. The most common symptomatic presentation is with early pregnancy loss and cervical incompetence. Infertility is not usually a problem with this type of malformation because implantation of the embryo is not impaired. A bicornuate uterus results from an abnormal development of the paramesonephric ducts. There is a partial failure of fusion of the ducts, resulting in a uterus divided into two horns [4].



Transvaginal ultrasonography showing a cross-section of a bicornuate uterus, with two cavities.

Out of 3 women, 2 had pregnancy & 1 had given birth to children.

### 3. Arcuate uteri:

The arcuate uterus is a form of a uterine anomaly or variation where the uterine cavity displays a concave contour towards the fundus. Normally the uterine cavity is straight or convex towards the fundus on anterior-posterior imaging, but in the arcuate uterus the myometrium of the fundus dips into the cavity and may form a small septation. The distinction between an arcuate uterus and a septate uterus is not standardized.

A screening study by Woelfer et al. [5] of women without a history of reproductive problems found that about 5% of women had an arcuate uterus when they defined an arcuate uterus as any fundal protrusion into the cavity that had an apical angle of more than 90 degrees.

In the 5 cases of Arcuate uterus women showed different conditions. 3 women were 2 times pregnant, 2 women were never able to conceive & 1 woman had miscarriage.

### CONCLUSION:-

Uterine anomalies in women undergoing hysteroscopy for abnormal uterine bleeding, showed that a müllerian anomaly could be detected in about 10% of women undergoing hysteroscopy for abnormal uterine bleeding, and confirmed that hysteroscopy is a valuable technique in assessing uterine cavity and showed that the prevalence of septate / bicornuate and arcuate uteri in women with abnormal uterine bleeding ranged between 3% to 7% and no history of reproductive problems [6].

When examining the various types of a uterine anomaly, the most common finding was bicornuate uterus; the second most common was septate uterus [7]. In current study most common uterine abnormality is arcuate uterus.

Müllerian anomalies are often treatable. Patients with MDAs are known to have a higher incidence of infertility, repeated first trimester, spontaneous abortions, IUGR, fetal malposition, preterm labor and retained placenta.

Congenital uterine malformations are more common than generally recognized. Knowledge concerning their prevalence and varieties is important in recognizing and managing the obstetric and gynaecologic complications.

### REFERENCES:-

1. Sotirios H. Saravelos, Karen A. Cocksedge and Tin-Chiu Li (2008). "Prevalence and diagnosis of congenital uterine anomalies in women with reproductive failure: a critical appraisal." *Human Reproduction Update* 14 (5): 415–29. doi:10.1093/humupd/dmn018.PMID 18539641
2. Müllerian agenesis: diagnosis, management, and treatment. Committee Opinion No. 562. American College of Obstetricians and Gynecologists. *Obstet Gynecol* 2013; 121:1134–7.
3. Li, S; Qayyum, A; Coakley, FV; Hricak, H (2000). "Association of renal agenesis and müllerian duct anomalies." *Journal of computer assisted tomography* 24 (6): 829–34. doi:10.1097/00004728-200011000-00001.
4. <http://radiopaedia.org/articles/bicornuate-uterus>.
5. Woelfer B, Salim R, Banerjee S, Elson J, Regan L, Jurkovic D (2001). Scholar search "Reproductive outcomes in women with congenital uterine anomalies detected by three-dimensional ultrasound screening" *Obstet Gynecol* 98 (6): 1099–103. doi:10.1016/S0029-7844(01)01599-X. PMID 11755560.
6. Maneschi F, Zupi E, Marconi D, Valli E, Romanini C, Mancuso S. Hysteroscopically detected asymptomatic müllerian anomalies. Prevalence and reproductive implications. *The Journal of reproductive medicine* 1995;40(10):684-648.
7. Meiling Hua, Anthony Odibo O, Ryan E Longman, George A Macones, Kimberly A Roehl, Alison G Cahill. Congenital uterine anomalies and adverse pregnancy outcomes. *MSCI American Journal of Obstetrics & Gynecology* 2011.