

Angiotensin converting enzyme inhibitors in the treatment of cTnTR141W transgenic mouse model of dilated cardiomyopathy.

Qianxiao Li¹, Qin Yu², Rongmei Na², Baiting Liu², Qianxiao Li^{1*}

¹Department of Cardiology, Zhejiang Hospital of Integrated Traditional Chinese and Western Medicine, Zhejiang, PR China

²Department of Cardiology, Affiliated Zhongshan Hospital of Dalian University, Liaoning, PR China

Abstract

Background: Angiotensin Converting Enzyme Inhibitors (ACEIs) are beneficial in patients with heart failure, yet their role after heart failure remains ambiguous. Particularly, the effects of ACEIs on cardiac function of dilated cardiomyopathy are unknown.

Methods: To establish the cTnTR141W transgenic mouse to make an animal model of dilated cardiomyopathy. 36 cTnTR141W transgenic mice were randomly divided into two groups: the experimental group and the placebo group. 18 transgene negative mice were used as controls. The three groups were taken captopril target dose/water as designed. Medications were routinely up-titrated over a period of 4 to 8 months.

Results: cTnTR141W mice had significantly larger hearts and poorer LV function than normal control group. LVSDV, LVEDV, LVIDs and LVIDd of mice in the experimental group were lower than those in the placebo group, while the EF%, FS%, SV and CO of mice in the experimental group were significantly enhanced than those in the placebo group. The survival rate of the experimental group is higher than that of the placebo group.

Conclusion: ACEIs is the key enzyme to increase the survival rate and efficiency of heart function improvement in cTnTR141W mice with heart dysfunction.

Keywords: Angiotensin converting enzyme inhibitors (ACEIs), Dilated cardiomyopathy (DCM), Cardiac troponin T (cTnT), Captopril.

Accepted on March 15, 2017

Introduction

Dilated cardiomyopathy (DCM) is a relatively common heart muscle disease with a prevalence of 1:2500 in adults leading to heart failure [1,2]. The disease is characterized by the dilation and thinning of the left ventricle accompanied with left ventricular systolic dysfunction [3]. The diagnosis is primarily based on evidence of dilation and impaired contraction of the left ventricle (left ventricular ejection fraction (LVEF)<45%) [4]. DCM has a poor prognosis with a five-year survival rate of approximately 50% after diagnosis [5]. Recent genetic studies have revealed that mutations in genes for cardiac troponin T (cTnT) cause DCM [6]. cTnT is a 37 KD protein that binds to Tropomyosin (Tm) to anchor the troponin complex in the thin filament and it thus serves as a vital link in the Ca²⁺ regulation of striated muscle contraction [7]. The enzyme linked immunoassay was developed for cTnT and showed its potential role towards cardiac myocytes as an AMI marker [8,9]. Proteases such as calpains, cathepsins and serine proteases have showed active role in degradation of cTnT [10]. It has been shown that the calcium activated cysteine proteases such as μ -calpain and caspase-3 are capable of degrading cTnT *in*

vitro [7]. Studies in the rat and mouse have shown that μ -calpain activation results in a 27 kDa fragment after *ex-vivo* ischemia and reperfusion of the isolated heart [11]. Furthermore, addition of inhibitors of μ -calpain showed a decrease in degradation of cTnT. Angiotensin Converting Enzyme Inhibitors (ACEIs) are critical in the treatment of heart failure as reduce the incidence of Left Ventricular Hypertrophy (LVH) and the control of high blood pressure which could several cardiovascular complications [12,13]. Reports have mentioned that the use of captopril as an ACEIs have shown benefits in cardiac function [14,15]. In this study, we established the cTnTR141W transgenic male mice as subjects to investigate the effect of ACEIs on cardiac function of dilated cardiomyopathy.

Materials and Methods

Animals models

The cTnTR141W transgenic male mice were established at the Institute of Laboratory Animal Sciences, CAMS and PUMC, maintained on a C57BL/6J genetic background. The transgenic

mice expressed high levels of the mutant human cTnTR141W DNA and showed ventricular chamber enlargement, systolic dysfunction, myocardial hypertrophy, and interstitial fibrosis at 4 months of age. Mice were housed individually in metabolic cages under standard conditions with free access to standard rat diet and drinking water ad libitum throughout the study. Eight weeks old mice were all evaluated by echocardiography. cTnTR141W transgenic mice with dilated LV and severely depressed LV function confirmed by echocardiography were provided for this study. After all, 36 mice completed the study. The experimental protocols were approved by the Ethical Committee for Animal Experimentation at the University and conformed to the Guide for the Care and Use of Laboratory Animals.

Identification of cTnTR141W transgenic mice genotyping by PCR analysis

Tail prick whole blood samples (<5 μ L each) obtained under ether anesthesia were spotted onto FTA filter papers (Truelab, Shanghai, China). The samples were washed twice in 200 μ L of mild buffer (Truelab, Shanghai, China) and then rinsed once in 200 μ L of DNase-free water by 1 min incubation at room temperature. The washes were discarded after each centrifugation at 12,000 rpm, 4°C for 10 s. The samples were then placed directly in 20 μ L genomic PCR mixture containing 300 pM of each primer, 2.5 mM of each dNTP, 2.5 mM magnesium chloride, 20 mM Tris/HCl buffer (pH 8.0) and 1 U LA Taq polymerase (TaKaRa). Transgene specific primers were 5'GAACAGGAGGAAGGCTGAGGATGAG and 5'TATTTCCAGCGCCCGGTGACTTTAG. PCR conditions were as follows: denaturation at 94°C for 5 min followed by 35 cycles of 98°C for 10 s, annealing at 58°C for 1 min and extension at 72°C for 3 min 10 s, followed by a final extension at 72°C for 5 min. PCR products was 369 bp.

Drug administration

36 mice with cTnTR141W were randomly divided into two groups: the placebo group and the experimental group. The experimental group took captopril target dose between 0.5 and 1.5 mg/kg/day divided every 8 h. the placebo group took water only. 18 mice with normal genotyping were considered as control group and taking water for control. Medications were routinely up-titrated over a period of 4 to 8 months, with subsequent dose adjustment made on the basis of hemodynamic tolerance and weight gain.

Echocardiography measurements

Mice were anesthetized with ether and LV function was assessed by means of echocardiography with a 30 MHz

phased-array transducer (Vevo770, Canada). The following parameters were measured from B- and M-mode tracing: Left Ventricular End-Systolic Diameter (LVIDs), Left Ventricular End-Diastolic Diameter (LVIDd), Left Ventricular End-Systolic Volume (LVESV), Left Ventricular End-Diastolic Volume (LVEDV), Interventricular Septum during diastole (IVSd), Interventricular Septum during systole (IVSs), Posterior Wall during diastole (PWd), Posterior Wall during systole (PWs), Stroke Volume (SV), Cardiac Output (CO), percent Ejection Fraction (EF%), Heart Rate (HR) and percent Fractional Shortening (FS%).

Survival analysis

Overall Survival (OS) was calculated from the date of 4 months old (taking medical) to the date of death or 8 months old (the last follow-up). Dissections were required when mice were died during the follow up for exclusion of other cause of death and recording the pathological changes of cardiac. Survival rates were calculated using the Kaplan-Meier method, and statistically significant differences in survival were identified using the log-rank test.

Statistical analysis

Data are presented as mean \pm SE. Mean values for more than three groups were compared by ANOVA, followed by a post-hoc Tukey's multiple comparison test. Survival data utilized the standard Kaplan-Meier analysis. The statistical analyses were performed using SPSS (Version 22.0). P values were two-sided and a value of <0.05 was considered to be statistically significant.

Results

The cTnTR141W transgenic mouse models have spread to the tenth generation which has stable DCM phenotypic and high positive rate (Figure 1).

Compared the echocardiographic data between baseline and follow up, cTnTR141W mice had significantly larger hearts and poorer LV function than normal control group (Table 1). LVSDV, LVEDV, LVIDs and LVIDd of mice in the experimental group were lower than those in the placebo group, while the EF%, FS%, SV and CO of mice in the experimental group were significantly enhanced than those in the placebo group.

The median follow-up was 3.6 months (range 0.1-4). There were 4 mice (22.22%) dead in the experimental group, 9 mice (50%) were dead in the placebo group, while none dead in the control group (Figure 1).

Table 1. Echocardiographic analysis.

Variable	The experimental group		The placebo group		The control group	
	Baseline	8 months	Baseline	8 months	Baseline	8 months

IVSd	0.77	0.72	0.76	0.78	0.67	0.66
IVSs	0.96	0.90	0.97	0.98	0.85	0.84
LVPWd	0.74	0.70	0.71	0.72	0.67	0.67
LVPWs	0.85	0.80	0.82	0.83	0.78	0.76
LVIDs	4.67	4.07	4.62	4.63	3.87	3.91
LVIDd	5.28	4.80	5.21	5.22	4.70	4.72
LVSDV	108.02	73.14	107.62	108.62	68.14	67.84
LVEDV	136.32	106.48	134.32	135.44	100.48	99.82
EF%	22.04	33.11	21.04	20.34	35.11	35.01
FS%	10.34	15.21	9.34	9.03	16.27	16.16
SV	27.29	34.32	26.29	25.82	35.32	35.26
CO	13.78	16.21	12.78	11.98	17.78	17.79

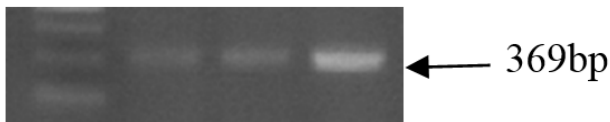


Figure 1. PCR analysis of the cTnTR141W transgenic mouse models.

Discussion

cTnT has been known as a marker of heart damage and myocardial cell death for more than 10 years [16]. In toxicological studies cTnT has been established as a biomarker for drug-induced cardiac injury [17,18]. Recently, DCM-linked mutation R141W was found in cTnT [19]. In this study, we established this mutation as animal model to investigate the effect of ACEIs on DCM.

Captopril as an ACEIs plays a role in the treatment for hypertension [20,21]. As overwhelming evidence implicating those ACEIs in the protection from adverse cardiac remodeling and heart failure development [22]. It is commonly used as a cardio protective drug to inhibit the conversion of angiotensin I [20]. Angiotensin I as a relatively inactive molecule to angiotensin II which is the major mediator of vasoconstriction and volume expansion induced by the renin-angiotensin system [23]. Captopril has been postulated as a free radical scavenger because of its terminal sulfhydryl group [24]. *In vitro* studies it indicated that the functions of captopril could increase the activities of antioxidant enzymes such as superoxide dismutase and glutathione peroxidase [25,26]. In this study we found that the cTnTR141W transgenic mice which took 4 months of captopril would significantly enhance cardiac function and reduce the incidence of heart failure and gradually improve the survival rate. However, 18 cTnTR141W transgenic mice were performed without any medicine apart from ethic and the heart functions were increasingly recession. Interestingly, preclinical studies have indicated that captopril might act as an antioxidant

to reduce inflammatory reactive oxygen species and reduced fibrosis in rat hearts early after irradiation, thus mitigate radiation-induced toxicity [27,28]. It would be the machine of ACEI in the protection of remodeling and heart failure development.

In this study we did not set up a heart failure control group with no wild type to further compare the therapeutic effectiveness of captopril on transgenic mice. As one shortcoming of this study, we need further research to demonstrate captopril.

To conclude, ACEIs increase the survival rate and efficiency of heart function of DCM. Captopril may be a promising strategy to reduce early cardiac complications of DCM in patients.

References

1. Ikeda Y, Inomata T, Fujita T, Iida Y, Nabeta T. Cardiac fibrosis detected by magnetic resonance imaging on predicting time course diversity of left ventricular reverse remodeling in patients with idiopathic dilated cardiomyopathy. *Heart Vessels* 2016; 31: 1817-1825.
2. Ambrosi P, Kreitmann B, Lepidi H. A novel overlapping phenotype characterized by lipodystrophy, mandibular dysplasia, and dilated cardiomyopathy associated with a new mutation in the LMNA gene. *Int J Cardiol* 2016; 209: 317-318.
3. Barison A, Emdin M, Masci PG. Increased extracellular volume fraction in nonischaemic dilated cardiomyopathy predicts worse outcomes independently of medical therapy. *J Cardiovasc Med (Hagerstown)* 2016; 17: 227.
4. Cao S, Zhou Q, Chen JL, Hu B, Guo RQ. The differences in left atrial function between ischemic and idiopathic dilated cardiomyopathy patients: A two-dimensional speckle tracking imaging study. *J Clin Ultrasound* 2016; 44: 437-445.
5. Forsha D, Slorach C, Chen CK. Patterns of mechanical inefficiency in pediatric dilated cardiomyopathy and their

- relation to left ventricular function and clinical outcomes. *J Am Soc Echocardiogr* 2016; 29: 226-236.
6. Kayvanpour E, Sedaghat-Hamedani F, Amr A. Genotype-phenotype associations in dilated cardiomyopathy: meta-analysis on more than 8000 individuals. *Clin Res Cardiol* 2016.
 7. Yildirim F, Esquinas AM. Cardiac troponin trends and severity in chronic obstructive pulmonary disease exacerbation: Are limits properly associated for intensive care unit outcome? *Lung India* 2016; 33: 583-584.
 8. Gilje P, Koul S, Thomsen JH. High-sensitivity troponin-T as a prognostic marker after out-of-hospital cardiac arrest-A Targeted Temperature Management (TTM) trial substudy. *Resuscitation* 2016; 107: 156-161.
 9. Marques MA, de Oliveira GA. Cardiac troponin and tropomyosin: structural and cellular perspectives to unveil the hypertrophic cardiomyopathy phenotype. *Front Physiol* 2016; 7: 429.
 10. Sandoval Y, Zakharova M, Rector TS. Frequency of increase in cardiac troponin levels after peripheral arterial operations (Carotid endarterectomy, abdominal aorta procedure, distal bypass) and their effect on medical management. *Am J Cardiol* 2016.
 11. Li F, Nie J, Lu Y. The impact of intermittent exercise in a hypoxic environment on redox status and cardiac troponin release in the serum of well-trained marathon runners. *Eur J Appl Physiol* 2016; 116: 2045-2051.
 12. Snauwaert E, Vande Walle J, De Bruyne P. Therapeutic efficacy and safety of ACE inhibitors in the hypertensive paediatric population: a review. *Arch Dis Child* 2016.
 13. Seth MK, Hussain ME, Pasha S, Fahim M. Effects of a novel ACE inhibitor, 3-(3-thienyl)-l-alanyl-ornithyl-proline, on endothelial vasodilation and hepatotoxicity in l-NAME-induced hypertensive rats. *Drug Des Devel Ther* 2016; 10: 1533-1542.
 14. Sun W, Zhang H, Guo J. Comparison of the efficacy and safety of different ace inhibitors in patients with chronic heart failure: A PRISMA-compliant network meta-analysis. *Medicine (Baltimore)* 2016; 95: 2554.
 15. Kumar S, Dietrich N, Kornfeld K. Angiotensin Converting Enzyme (ACE) inhibitor extends *Caenorhabditis elegans* life span. *PLoS Genet* 2016; 12: 1005866.
 16. Gong X, Wang P, Wu Q, Wang S, Yu L, Wang G. Human umbilical cord blood derived mesenchymal stem cells improve cardiac function in cTnT (R141W) transgenic mouse of dilated cardiomyopathy. *Eur J Cell Biol* 2016; 95: 57-67.
 17. Bertsch T, Janke C, Denz C. Cardiac troponin I and cardiac troponin T increases in pigs during ischemia-reperfusion damage. *Exp Toxicol Pathol* 2000; 52: 157-159.
 18. Jiang Y, Wang D, Zhang G, Wang G, Tong J, Chen T. Disruption of cardiogenesis in human embryonic stem cells exposed to trichloroethylene. *Environ Toxicol* 2015.
 19. Lu D, Ma Y, Zhang W. Knockdown of cytochrome P450 2E1 inhibits oxidative stress and apoptosis in the cTnT (R141W) dilated cardiomyopathy transgenic mice. *Hypertension* 2012; 60: 81-89.
 20. Abbasi S, Yousefi G, Ansari AA, Mohammadi-Samani S. Formulation and in vitro evaluation of a fast-disintegrating/sustained dual release bucoadhesive bilayer tablet of captopril for treatment of hypertension crises. *Res Pharm Sci* 2016; 11: 274-283.
 21. Natalin HM, Garcia AF, Ramalho LN, Restini CB. Resveratrol improves vasoprotective effects of captopril on aortic remodeling and fibrosis triggered by renovascular hypertension. *Cardiovasc Pathol* 2016; 25: 116-119.
 22. Abd Allah ES, Gomaa AM. Effects of curcumin and captopril on the functions of kidney and nerve in streptozotocin-induced diabetic rats: role of angiotensin converting enzyme I. *Appl Physiol Nutr Metab* 2015; 40: 1061-1067.
 23. Braszko JJ, Karwowska-Polecka W, Halicka D, Gard PR. Captopril and enalapril improve cognition and depressed mood in hypertensive patients. *J Basic Clin Physiol Pharmacol* 2003; 14: 323-343.
 24. Carvalho CR, Thirone AC, Gontijo JA, Velloso LA, Saad MJ. Statement of retraction. effect of captopril, losartan, and bradykinin on early steps of insulin action. *Diabetes* 1997; 46: 1950-1957.
 25. Cho WK, Shin SW, Kim SY. Immunomodulatory effect of captopril and local irradiation on myeloid-derived suppressor cells. *Radiat Oncol J* 2016; 34: 223-229.
 26. Aziriova S, Repova Bednarova K, Krajcirovicova K. Doxorubicin-induced behavioral disturbances in rats: protective effect of melatonin and captopril. *Pharmacol Biochem Behav* 2014; 124: 284-289.
 27. Bojarska J, Maniukiewicz W, Fruzinski A, Sieron L, Remko M. Captopril and its dimer captopril disulfide: comparative structural and conformational studies. *Acta Crystallogr C Struct Chem* 2015; 71: 199-203.
 28. Furqan Muhammad I, Mahmood A, Aysha R. Synthesis and in vitro characterization of hydroxypropyl methylcellulose-graft-poly (Acrylic acid/2-acrylamido-2-methyl-1-propanesulfonic acid) polymeric network for controlled release of captopril. *Acta Pol Pharm* 2016; 73: 183-196.

*Correspondence to

Qianxiao Li

Department of Cardiology

Zhejiang Hospital of Integrated Traditional Chinese and Western Medicine

PR China